



The New York State Poison Centers

# TOXICOLOGY

LETTER

COMPRISING THE NEW YORK CITY AND UPSTATE NEW YORK POISON CENTERS

## Gold Mine Misadventure?

Contributed by: Ross Sullivan, MD Medical Toxicology Fellow, Upstate Poison Center, Syracuse, NY.

### Case

Patient HB is a 36 year old male who presents to the Emergency Department complaining of nausea and vomiting for one week's duration. Over the past several days, he has also developed diarrhea, fatigue and mild intermittent tremors of his hands. His physical examination is significant for sunken eyes, and dry mucous membranes. He has a petechial rash on his face, thought to be due to his vomiting. He also has hyperactive bowel sounds, and a mild, intermittent tremor most notable at his hands bilaterally. The remainder of his examination is unremarkable, including vital signs.

The patient takes no medications or over the counter supplements, and his family history is unremarkable. He works as a handy man for a nearby apartment building. His hobbies include playing the drums, swimming, and geology. He denies any travel other than a trip to Mexico where he was involved in some gold extraction in an uncontrolled setting. He notes he did have a cough while in Mexico one week ago.

An electrocardiogram and chest radiograph are read as normal. Basic metabolic panel reveals sodium of 132 mmol/L, potassium 3.9 mmol/L, chloride 96 mmol/L, BUN 26 mg/dl, creatinine 1.4 mg/dl, glucose 99 mg/dl.

## Program Announcements ♦♦

**UNY:** The 2012 Toxicology Teaching Day is Scheduled for 11/7/12. Please mark your calendars!!

**NYC:** Consultants Case Conference • The first Thursday of the Month from 2-4pm

Please call administrative telephone numbers for more information and to attend remotely.

## Toxicology Advice Centers ♦♦

Administrative Phone Numbers - To obtain a consult in your area, call 1.800.222.1222.

Upstate New York Poison Center (UNY) ..... 315.464.7078 • [www.upstatepoison.org](http://www.upstatepoison.org)

New York City Poison Control Center (NYC) ..... 212.447.8152

### What are some problems associated with gold mining?

Mining for gold is a profitable and important industry, and in many developing countries, is of paramount importance to the economic survival of certain sectors of the population. Artisan gold mining or "small scale mining" is common in these areas, where miners use hand tools, manual labor, and other readily available techniques to mine and extract gold. Limited resources and training, the availability of cheap labor along with potentially hazardous methods of extractions and processing of minerals can lead to significant threats to both environmental and human health.<sup>1</sup>

Aside from workplace trauma, working in these mines can also pose other significant health risks. Artisan gold mining can expose workers to various heavy metals.

### How and why is mercury used for gold smelting ?

Since at least the time of the ancient Romans, mercury is often found in artisan mining during processing of gold and silver ores, when mercury is used to amalgamate these precious metals.<sup>1</sup> Having a low boiling point and being stable as a liquid, mercury is often the choice for amalgamation. Miners submerge their mined ore in mercury, with the mercury attracting micro-gold particles to form Au-Hg amalgam. The Hg is subsequently boiled off, leaving their desired gold behind.

It is estimated that during the amalgam process, 40% of mercury is lost into the pan ponds, and eventually finds its way into the sediments and surface and underground water.<sup>1</sup> The remaining 60% of mercury is released directly into the air

Continued on page 2

when the Au-Hg amalgam is being heated during the purification stage, posing a significant risk for inhalation by workers.<sup>1</sup>

### What are the three types of mercury and what are their toxicities?

The principle ore of the element mercury within the earth's crust is mercuric sulfide.<sup>2</sup> Humans may be exposed to various types (species) of mercury, including the inorganic mercurous ( $\text{Hg}^{1+}$ ) and mercuric ( $\text{Hg}^{2+}$ ) salts.

Toxicity arises from mercury's ability to bind to sulfhydryl groups within the human body and disrupt the proper functioning of sulfhydryl-containing enzymes.<sup>2</sup>

Routes of exposure, toxicity, and ultimately, treatment strategies and medical sequelae vary with the species of mercury involved.

#### Inorganic Mercury

Inorganic mercury exists as a salt (such as Mercuric Chloride  $\text{HgO}_2$ ), and has been used in disinfectants, paints and dyes. Oral ingestion causes caustic damage to the gastrointestinal tract. Dermal absorption of inorganic mercury found in creams has been described. Although only 10–40% of inorganic mercury is absorbed through the gut, this amount is sufficient enough to result in systemic toxicity including renal injury.<sup>3</sup>

#### Elemental Mercury

Elemental mercury has been used in precision instruments, including barometers and thermometers. Stable properties as a liquid over a wide range of temperatures allow elemental mercury to be used for such purposes.<sup>2</sup> Elemental mercury evaporates slowly at standard temperatures, but when heated, releases even more vapor, which can be toxic.<sup>3</sup>

Ingestion of elemental mercury, such as oral exposure to the contents of a broken thermometer, rarely leads to toxicity, since gastrointestinal absorption is minimal. Inhalational exposure, however, can lead to significant toxicity. Absorption via the pulmonary route leads to a multitude of effects. High exposures can be directly toxic, and lower exposures, although not toxic to the lungs, can still have systemic symptoms. Respiratory symptoms following acute inhalational exposure to high concentrations can lead to cough, chills, and shortness of breath; more severe complications such as pneumonitis, pulmonary edema, and restrictive lung disease can also occur. Alveolar damage occurs due to a combination of direct toxic effects as well as the indirect effects of mercury binding to sulfhydryl groups of enzymes and proteins of alveolar structures.<sup>3</sup>

Due to high lipophilicity, alveoli can absorb up to 80% of inhaled elemental mercury. Once it enters the systemic circu-

lation, elemental mercury is oxidized in various tissues to mercurous ( $\text{Hg}^{+1}$ ) and mercuric ( $\text{Hg}^{+2}$ ) cations. The lipophilic elemental mercury readily enters the central nervous system (CNS), where it is oxidized to the less lipophilic mercurous ( $\text{Hg}^{+1}$ ) and mercuric ( $\text{Hg}^{+1}$ ) species, which accumulate here, since they cannot cross back over the blood brain barrier.<sup>3</sup>

Human exposure to elemental mercury can also lead to renal toxicity, tremor, gingivitis, and erethism, a syndrome characterized by shyness, personality changes, and memory loss.<sup>2</sup>

Elemental and Inorganic toxicity can also lead to acrodynia, a condition that is characterized by a wide range of clinical manifestations, including painful and pruritic dusky pink discoloration of the hands and feet<sup>2</sup>, a pink maculopapular skin rash, excessive sweating, hypertension, and tachycardia.<sup>3</sup> This condition is also known as Pink disease. Further, a similar constellation of symptoms have been described in children who had calomel ( $\text{HgCl}$ ) teething powders applied.

#### Organic Mercury

Organic mercurials include aryl, short chain alkyl, and long chain alkyl forms. Traditionally found in fungicides (banned in the United States since 1990), organic mercury can lead to symptoms following chronic exposure. The discharge of industrial waste contaminated with mercury has introduced mercury into the aquatic food chain. Inorganic Hg is organified by microbes. This bioaccumulates up the food chain and human exposure occurs through consumption of contaminated fish. Also, emissions from burning coal is the largest source of mercury entering waterways in the United States today.

Toxicity of absorbed organic mercurials primarily affects the central nervous system with profound neurologic effects, including parasthesias, ataxia, and vision abnormalities. The most severely affected patients being children exposed to high levels in utero, during critical CNS development, who were found to be mute, with rigid posture punctuated only by spontaneous crying, primitive reflexive movements, or feeding efforts.<sup>4</sup> This most severe form of organic mercurial poisoning was seen with Methylmercury poisoning in the devastating neurologic disease seen in the 1950s in Minamata Bay, Japan following consumption of contaminated seafood. Exposed infants exhibited decreased birth weight and muscle tone, profound developmental delay, seizure disorders, deafness, blindness, and severe spasticity.<sup>4</sup> Widespread exposure also occurred in Iraq in 1972, when methylmercury-treated seed-grain meant for planting was mistakenly used to prepare bread.

## Buprenorphine: Can it be Deadly in a Dose?

Hong Kim, M.D., Susi Vassallo, M.D., Lewis Nelson, M.D.

A 13 month-old boy with no past medical history is found lethargic in his crib and is brought to the emergency department (ED). Approximately 2 hours prior to presentation, the child was found with an open container of buprenorphine/naloxone (Suboxone). The parent noted that pill fragments were present in the child's mouth; these were removed immediately. In the ED, his vital signs are: BP, NA; HR, 120 beats per minute; RR, 10 breaths per minute; T, 98.2°F; O<sub>2</sub> sat: 94% on room air. The physical examination is notable for lethargy but the child is arousable to tactile stimuli. There are no signs of trauma. Pupils are pinpoint. The cardiovascular and pulmonary examinations are normal. The patient is able to move all of his extremities spontaneously.

### What is buprenorphine and why is it useful?

Buprenorphine is a partial mu-opioid receptor agonist and kappa-opioid receptor antagonist that is increasingly being used as an alternative to methadone as maintenance therapy for opioid dependence. Although buprenorphine has been available for decades for the treatment of pain, it has only been used since 2002 for this new indication. Buprenorphine has approximately 1000 fold greater receptor affinity compared to morphine and is 20 to 50 times more potent than morphine.<sup>4</sup> The presence of active metabolites, slow dissociation from the receptor, and a prolonged elimination half-life (mean 37 hours) contributes to its long duration of action.<sup>4</sup> These characteristics of buprenorphine also explain the higher naloxone dose requirement for clinical reversal of respiratory depression.<sup>1,5</sup>

Buprenorphine has a theoretical advantage of having a "ceiling effect" on its ability to produce respiratory depression. This means that unlike full opioid agonists such as methadone, excessive dosing may be safer. In one study, increasing the dose of buprenorphine decreased the ventilation of healthy adult volunteers by 50%. Administration of higher buprenorphine doses did not cause any further ventilatory depression. In comparison, fentanyl caused a dose-dependent respiratory depression and apnea.<sup>6,7</sup>

Buprenorphine is available in a combined formulation with naloxone in a 4:1 ratio (buprenorphine to naloxone: 2 mg/0.5 mg and 8 mg/2 mg). The combined formulation with naloxone deters intravenous misuse.<sup>1,2</sup> Moreover, unlike methadone maintenance programs, which require daily visits to a federally certified clinic, buprenorphine/naloxone can be prescribed by certified physicians for unsupervised use. The buprenorphine/naloxone combination is available in a sublingual formulation in the U.S. Naloxone is not systemically bioavailable by this route. In children, buccal absorption is the major route

of exposure and is believed to have similar bioavailability as sublingual administration.

### What is the risk of buprenorphine exposure in children?

The number of unintentional buprenorphine exposures in children is increasing along with the availability of buprenorphine. According to data from the American Association of Poison Control Centers (AAPCC), reported pediatric (age < 6 years) buprenorphine exposures increased exponentially between 2002 (2 cases) and 2008 (907 cases). Meanwhile, exposures to methadone in the same age group doubled (155 cases to 332 cases) during the same six-year period.<sup>2</sup>

Although the theoretical "ceiling effect" in respiratory depression has been demonstrated in small studies with healthy adults, there are reports of buprenorphine associated deaths among adults with opioid abuse history. In the pediatric population, cases of significant respiratory depression requiring naloxone administration and intubation have occurred after 1 or 2 tablets.<sup>1-3,10</sup> There is no evidence to support that a "ceiling effect" applies to the pediatric population.

### What common medications are dangerous to a child in a single adult dose?

Several types of medication can cause severe toxicity in children even after the ingestion of a single adult dose. Exposure to therapeutic adult doses frequently results in an overdose in children. For instance, exposure to a single therapeutic adult dose of phenothiazine such as chlorpromazine can cause CNS depression and hypotension in children. However, the danger to children depends not only on the dose itself but also on the pharmacokinetic and pharmacodynamic properties of each agent. For example, antihypertensive and oral hypoglycemic agents are among the most commonly prescribed medications in adults. Although not all antihypertensive medications are dangerous in a single adult dose in a child, sustained release calcium channel and beta-adrenergic antagonists in particular can result in cardiovascular collapse even hours after ingestion. Clonidine, an imidazoline derivative used as an anti-hypertensive agent in adults, stimulates central alpha 2-adrenergic receptors. A single tablet may cause bradycardia, hypotension and opioid like central nervous system and respiratory depression in children. Among the antidiabetic agents, sulfonylureas can cause severe and protracted hypoglycemia.

Other dangerous medications in children after a single adult dose exposure are listed in table 1. In general, pediatric exposure to sustained release agents poses a particular concern as clinical signs and symptoms of toxicity can be delayed.

Continued on page 4

## Buprenorphine: Can it be Deadly in a Dose?

Continued from page 3

Moreover, agents with active metabolites or a delayed elimination half life can produce prolonged clinical toxicity. Appropriate GI decontamination, antidote administration, or other clinical interventions should be performed in conjunction with the regional poison control center's consultation.

**Table 1. Medications with significant toxicity in children after single adult dose exposure**

Benzocaine
Beta-adrenergic antagonists (sustained release)
Calcium channel antagonists (sustained release)
Clonidine
Diphenoxylate and atropine (Lomotil)
Methanol/ethylene glycol
Monoamine oxidase inhibitors
Opioids
Phenothiazines
Quinine or chloroquine
Theophylline

### What is the spectrum of buprenorphine toxicity in children?

Buprenorphine can induce serious toxicity even in single or partial tablet exposure (0.07 mg/kg to 0.4 mg/kg) in children.<sup>3,10</sup> Approximately 90% of the symptomatic patients with buprenorphine exposure experienced CNS depression, miosis, or vomiting.<sup>1,3</sup> In a case series of children under 2 years old exposed to one or two tablets, all required naloxone administration or intubation.<sup>10</sup> Additionally, there are reports of delayed onset of respiratory depression in toddlers, as late as 6 hours post exposure.<sup>2,10</sup> Therefore, clinicians must rely on the history, clinical findings, and understanding of the pharmacology of buprenorphine to determine the appropriate course of management.

Although there is limited evidence available to guide the management of buprenorphine exposure in children, it is prudent to admit such children for 24 hours of clinical observation.

### Can naloxone reverse the CNS and respiratory effect of buprenorphine toxicity?

Naloxone is a competitive mu-opioid receptor antagonist that is commonly used to reverse the ventilatory depressant effects of opioids. Although small doses of naloxone administered intravenously will readily reverse most opioid-induced clinical effects, naloxone does not predictably reverse those of buprenorphine. In a small prospective study of healthy

adult volunteers, administration of 0.8 mg of naloxone did not reverse the respiratory depression caused by 0.2 mg of buprenorphine.<sup>5</sup> Full reversal of respiratory depression was only achieved when 2 to 4 mg of naloxone was administered. Furthermore, the onset of reversal appeared to be delayed.<sup>10</sup> Interestingly, administration of high doses of naloxone (> 4 mg) resulted in decreased reversal activity, resulting in an inverse U-shaped dose-response curve.<sup>5</sup> A limitation of this study was that naloxone was infused over 30 minutes and not administered by the more customary intravenous bolus. In summary, naloxone appears to reverse the effects of buprenorphine, but higher naloxone doses may be required. The exact reason remains unclear, but buprenorphine's high receptor affinity and slow dissociation may play a role.

Several reports of pediatric buprenorphine intoxication suggest that 0.04 mg/kg to 0.1 mg/kg of naloxone (currently recommended initial pediatric dose) administration successfully reversed respiratory depression.<sup>3,10</sup> Despite a lack of evidence and limited clinical experience using naloxone to reverse buprenorphine-induced respiratory depression, it seems reasonable to start by administering up to 0.1 mg/kg until the dose-reversal relationship is better characterized. More naloxone may be required but physicians should keep in mind that administering doses greater than 4 mg may result in reduced reversal activity.

### Case resolution:

Despite the administration of two bolus doses of 0.4 mg of naloxone, the respiratory rate continued to decrease. As hypoxemia developed, ED physician intubated the patient for ventilatory support. The child remained on ventilatory support for 16 hours and was subsequently extubated without complications. No additional naloxone was administered during the hospital stay and the patient recovered without any complications. Child Protective Service was contacted.

#### Reference:

1. Hayes BD, K.-S.W., Doyon S, *Toxicity of buprenorphine overdoses in children*. *Pediatrics*, 2008. 121(4): p. 782-786.
2. Boyer EW, M.-K.E., Marcus S, *Methadone and buprenorphine toxicity in children*. *The American Journal on Addictions*, 2009. 19: p. 89-95.
3. Pedapati EV, B.S., *Toddlers requiring pediatric intensive care unit admission following at-home exposure to buprenorphine/naloxone*. *Pediatrics Critical Care Medicine*, 2011. 12(2): p. 102-107.
4. Orman JS, K.G., *Buprenorphine/Naloxone*. *Drugs*, 2009. 69(5): p. 577-607.
5. van Dorp E, Y.A., Sarton E, Romberg R, Olofsen E, Teppema L, Danhof M, Dahan A, *Naloxone reversal of buprenorphine-induced respiratory depression*. *Anesthesiology*, 2006. 105: p. 51-57.

Continued on page 6



## An Inappropriate Snack

Payal Sud, M.D., Lewis Nelson, M.D.

A previously healthy 60 year-old woman presents to the emergency department (in December) complaining of nausea, vomiting, and diffuse abdominal pain. She states that 12 hours earlier she chewed and swallowed three “seeds” growing on a plant in her backyard. She acknowledged that she did this because “they looked tasty” and did not have any intent of self-harm. The gastrointestinal distress began 6 hours post-ingestion and she waited 6 more hours before coming to the ED. In the ED her abdominal pain is minimal but she has one episode of emesis. Her vital signs are: BP, 136/75 mmHg; HR, 79 beats/min; RR, 20 breaths/min; T, 98.1°F; and SPO<sub>2</sub> 100%. Her mucous membranes are dry but otherwise her physical examination is normal.

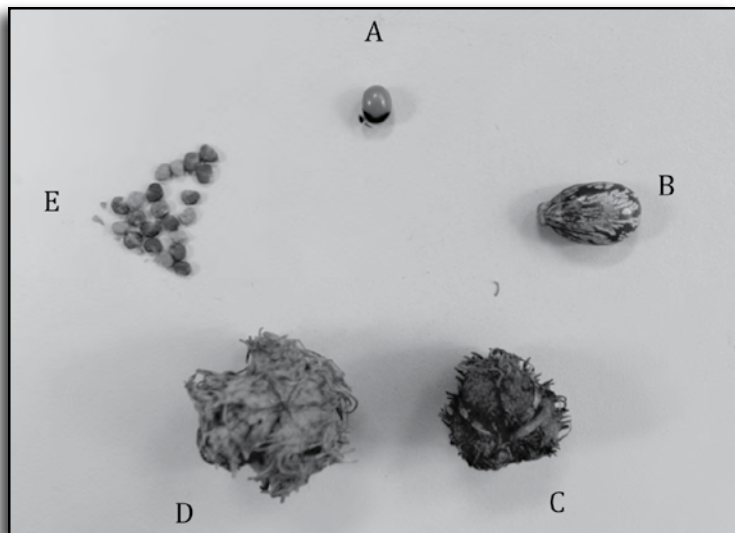


FIGURE: (A) *Abrus precatorius* (B) castor bean (C) dried castor bean pod (D) dried Jimsonweed pod (E) Jimsonweed seeds

### What are these seeds and what is their toxicity?

The castor bean plant (*Ricinus communis*) is indigenous to tropical regions but is also grown worldwide as an ornamental plant. It grows rapidly, exceeding 8 feet in a single temperate growing season, and has a burgundy stem with large (over 1 foot across), dark green, and deeply scalloped leaves. Towards the autumn, spiky seed pods grow and eventually mature to contain three individual seeds each. The seeds, called castor beans, are not by some definitions true beans since they are inedible. Castor beans are elliptical in shape, brown, and variegated, resembling a tick (“ricinus” is Latin for tick). The shell of the bean, while soft, is tough and water impervious. Castor beans are the source of castor oil, which has multiple uses including laxatives, lubricating oil for jet engines, (the initial Castrol motor oil), and as a solvent for paints and varnishes to name a few.

Ricin is the toxin that remains when castor oil is separated from the bean.; the oil is toxin-free. It is a protein toxin consisting of 2 chains: A chain and B chain linked by a disulfide bond. The B chain has binding sites for cell surface galactose residues, which allows ricin to bind to cell surfaces. After binding to glycoproteins and glycolipids, ricin is endocytosed and transported within endosomes. Some of the ricin molecules enter the endoplasmic reticulum, where the A and B chains are cleaved. The A chain translocates to the cytosol and binds ribosomal RNA (rRNA) inhibiting protein synthesis irreversibly and causing cell death.

A similar toxin, abrin, is found in the Rosary pea, derived from the plant *Abrus precatorius*. These 1 cm oblong, red seeds with a black “cap” at one end are commonly used as prayer beads when strung together and may be used to decorate small trinkets and other objects. Abrin has a mechanism of action similar to ricin, but is more potent.<sup>9</sup>

Jimsonweed (*Datura stramonium*), grows naturally throughout the U.S., also develops spiked pods towards the end of its growing season. The flowers of this plant are large and fluted (thus the moniker “angel’s trumpet”). There are dozens of small seeds within the pods that contain anticholinergic alkaloids such as atropine and scopolamine. Since these are often proffered on websites as “natural hallucinogens” they are sought by teens, who are unaware of the other significant clinical effects (the anticholinergic toxidrome) associated with their ingestion<sup>10</sup>.

### What is the typical clinical picture following ricin ingestion?

When castor beans are swallowed whole, ricin is not released. However, mastication of the beans prior to swallowing releases ricin. Rosary peas are similarly only toxic if chewed, although the hole created by stringing the seeds may provide an exit portal for toxin if ingested. The oral absorption of ricin is poor, and ingestion typically causes gastrointestinal symptoms within 4–6 hours of exposure. The most common cause of death following ingestion is hypovolemia from dehydration. Fortunately castor bean ingestion is rare in humans, although it is more frequent in dogs and other household pets. In humans and animals, absorbed ricin can cause multi-organ dysfunction including hepatotoxicity, nephrotoxicity, cardiovascular toxicity and hemolysis. In mice the median lethal dose (LD<sub>50</sub>) is suggested to be 30 mg/kg.<sup>1</sup> Case reports demonstrate that the lethal oral dose in humans ranges from 1–20 mg/kg. It is commonly considered that about 8 beans is lethal for an adult, although a few as 2 has been reported.<sup>1</sup>

Continued on page 6

## An Inappropriate Snack

Continued from page 5

Parenterally administered ricin carries substantial risk of morbidity and mortality. In the most famous case, Georgi Markov, a Bulgarian dissident, was unknowingly impaled with a tiny metal sphere through an umbrella.<sup>4</sup> Several days later he died of multisystem organ failure, and autopsy revealed the sphere with a drill hole through its diameter in his popliteal fossa. Speculation that the sphere contained ricin was confirmed after the breakup of the USSR. Recent concerns include terrorist activity dispersing airborne, powdered ricin that can be inhaled and result in lethal pulmonary toxicity or systemic absorption.

### What is the treatment of ricin poisoning?

There is no specific antidote or treatment for ricin toxicity. Single-dose activated charcoal can be considered although its efficacy for ricin poisoning is unknown.<sup>7</sup> If the patient presents shortly after ingestion and has not yet had emesis, gastric lavage should be considered, although its utility is unknown. Oral activated charcoal is similarly unproven but should be administered to most such patients. Hemodialysis does not remove ricin. The mainstay of treatment is supportive and directed towards resolution of symptoms and maintenance of normal vital signs. Renal function should be monitored. Once affected, patients are typically symptomatic for up to 36 hours. If a patient is asymptomatic 12 hours post-ingestion, it is unlikely that they will develop delayed gastrointestinal toxicity, although delayed hepatotoxicity has been reported in one child after 48 hours of ingestion.<sup>2</sup>

Development of a ricin vaccine is of high military interest, and RiVax was developed in 2004. The vaccine consists of a genetically modified, enzymatically inactivated ricin chain A. The vaccine completed its phase 1A trial in 2006, where it was shown to be safe and to induce antibodies in healthy human volunteers.<sup>8</sup> RiVax has been granted orphan drug status and currently 1B trials are underway.

### Case conclusion

The patient received 4 mg of ondansetron to control her nausea, followed by 50 g of activated charcoal. She tolerated the activated charcoal and was admitted to the medicine floor for overnight observation. By the next morning her symptoms had resolved and all her laboratory studies were normal. She was discharged home with a follow-up scheduled with her primary care doctor.

### References

1. Audi J, et al. Ricin Poisoning: A Comprehensive Review. *JAMA*. 2005 (294)18; 2342-2351
2. Palatnick W, Tenebein M. Hepatotoxicity from Castor Bean Ingestion in a Child. *Clin Tox*. 2000 38(1); 67-69
3. Doan LG. Ricin: Mechanism of Toxicity, Clinical Manifestations, and Vaccine Development. A Review. *Journal of Toxicology*. 2004 (42)2; 201-208
4. Papaloucas M, et al. Ricin and the Assassination of Georgi Markov. *Pakistan Journal of Biological Sciences*. 2008 (19); 2370-2371
5. Lord, JM et al. Ricin: structure, mode of action, and some current applications. *FASEB journal*. 1994 8(2):201-8
6. Coopman, V et al. Suicidal death after injection of a castor bean extract (*Ricinus communis* L.). *Forensic Science International*. (2009) e13-e20.
7. Chyka, PA et al. Position statement: single-dose activated charcoal: American Academy of Clinical Toxicology; European Association of Poisons Centres and Clinical Toxicologists. *J Toxicol Clin Toxicol*. 1997 (35); 721-741.
8. Vitetta, ES et al. A pilot clinical trial of a recombinant ricin vaccine in normal humans. *PNAS*. 2006 103(7):2268-2273
9. Dickers, KJ et al. Abrin poisoning. *Toxicol Rev*. 2003 22(3):137-42
10. Palmer, ME and Betz JM, *Plants*. Goldfrank's Toxicological Emergencies, Ninth Edition. 2011. McGraw Hill.

## Follow-Up from the New York City Poison Control Center Consultants' Conference of November 3, 2011

### Buprenorphine: Can it be Deadly in a Dose?

Continued from page 4

6. Dahan A. Opioid-induced respiratory effects: new data on buprenorphine. *Palliative Medicine*, 2006. 20: p. s3-s8.
7. Dahan A, Y.A., Bijl H, Romberg R, Sarton E, Teppema L, Olofsen E, Danhof M. Comparison of the respiratory effects of intravenous buprenorphine and fentanyl in humans and rats. *British Journal of Anaesthesia*, 2005. 94(6): p. 825-834.
8. Brown, S., et al., Buprenorphine Metabolites, Buprenorphine-3-glucuronide and Norbuprenorphine-3-glucuronide, Are Biologically Active. *Anesthesiology*, 2011. 115(6): p. 1251-1260.
9. Yassen A, K.J., Olofsen E, Suidgeest E, Dahan A, Danhof M, Pharmacokinetic-pharmacodynamic modeling of the respiratory depressant effect of norbuprenorphine in rats. *The Journal of Pharmacology and Experimental Therapeutics*, 2007. 321(2): p. 598-607.
10. Geib AJ, B.K., Ewald MB, Boyer EW. Adverse effects in children after unintentional buprenorphine exposure. *Pediatrics*, 2006. 118: p. 1746-1751.

### How is mercury measured or detected?

The diagnosis of mercurialism can be challenging. Due to early non-specific symptoms and no commonly-seen early routine laboratory abnormalities, detection is difficult. If mercury toxicity is suspected, a complete history, including occupational exposures, ritualistic practices, herbal and traditional medications, hobbies, and access to mercury-containing products should be assessed.

There are several options available when testing for mercury. Whole blood concentrations can be used after acute exposure to all form of mercury. This method is able to detect the mercury concentration within the red blood cell where mercury is likely to accumulate.<sup>3</sup> Whole blood can also be used to assess acute, intense exposure to elemental and inorganic mercury. These values will become less useful as time goes on, as distribution from blood into other tissues will occur.<sup>3</sup>

Urine mercury concentrations can be useful to confirm inorganic and elemental mercury exposure. There may be a rough correlation between urine level and exposure history, but the relationship to total body-burden is poor.<sup>4</sup> Hair analysis has been used as a tool for measuring mercury burden since it accumulates in the hair. Since hair will reflect both past exposure, and binds environmental mercury avidly, the reliability of this method is questionable and interpretation must be made cautiously.<sup>4</sup>

### How is mercury toxicity treated?

The most important intervention in eliminating toxicity from mercury is removal from the environment and exposure.

Treatment of mercury poisoning generally centers on the use of chelation agents. Chelation describes a process in which an agent (chelator from the Greek Chele = Claw) is administered that can reduce the heavy metal burden of the body by forming metal-chelator complexes which are then readily excreted. Chelating agents contain thiol groups which compete with endogenous sulfhydryl groups for binding mercury.<sup>3</sup>

D-Penicillamine is a monothiol and can be used to chelate mercury, most often used for elemental. The D-penicillamine-mercury moiety is excreted in the urine. Side effects include GI distress, leukopenia, thrombocytopenia, and proteinuria, which limit its usefulness.<sup>3</sup>

BAL or British anti-lewisite (2,3-dimercapto-1-propanol) was developed during WW II as an antidote for lewisite, an arsenic-containing chemical warfare agent. BAL, only available in intra-muscular (IM) form mixed in peanut oil, contains two sulfhydryl groups which combines to various metals; including inorganic mercury. BAL is not indicated for elemental mercury toxicity, because animal models have shown elevated brain elemental mercury levels secondary to redistribution. Toxic effects include hypertension, tachycardia, GI symptoms, and allergic reactions in those with peanut allergies.<sup>3</sup>

2,3-Dimercaptosuccinic acid (Succimer) is an orally-administered chelator that has been used to treat poisoning from all three forms of mercury.<sup>5</sup> It improves survival, decreases renal damage, and enhances elimination of mercury in animals following exposure to inorganic mercury and methylmercury.<sup>5</sup> Adverse effects are mild, and include GI symptoms such as nausea, vomiting, flatus, and diarrhea. Mild elevations in hepatocellular enzymes may occur, and typically return to baseline after therapy is discontinued.<sup>3</sup>

DMPS (2,3-dimercapto-1-propanesulphonate) is a water soluble dimercaprol derivative that is used in Europe. N-acetyl-d,l-penicillamine (NAP) is an investigational analog of D-penicillamine, and may be more effective than D-penicillamine.<sup>4</sup>

Other treatments are also under investigation. Animal studies investigating NAC have shown an increase in urinary excretion rates of organic compared with inorganic mercury.<sup>3</sup>

Anti oxidants, including vitamin E and N,N-diethyl-p-phenylenediamine sulfate (N,N'-DPPD) have shown some protective benefit in rats.<sup>3</sup>

Corticosteroids have also been used in the case of mercury-induced nephritis and inhaled mercury vapor toxicity; their effectiveness is unknown.<sup>3</sup>

### Case resolution

Patient HB was admitted to the hospital, where mercury poisoning was suspected. The patient received symptomatic care, and had an initial urine mercury level of 170.5 mcg/g Cr (reference <35 mcg/g Cr). Unfortunately a blood mercury level was recommended but was never obtained.

The patient received a 19 day course of succimer, and over the course of treatment, had resolution of his tremors.. Repeat urine mercury post-succimer revealed a level of 50.3 mcg/g Cr.

The patient had reemergence of his tremor, and a second course of succimer was recommended. The patient, however, could not afford any further treatment, and has since been lost to follow up.

#### References:

1. Ogola, J; Mittulah, W; Omulo, M. *Impact of Gold Mining on the Environment and Human Health: A Case Study in the Migori Gold Belt, Kenya.* *Environ Geochem Hlth* 24:141-158, 2002
2. Baum, C. *Treatment of Mercury Intoxication.* *Curr Opin Pediatr* 11:256-268, 1999
3. Pandalai, S; Morgan, B. *Case Files of the Emory University Medical Toxicology Fellowship: Inhalational Mercury Toxicity from a Traditional Vietnamese Product.* *J Med Toxicol* 7:295-305, 2011
4. Sue, Y. (2011). *Mercury.* *Goldfrank's Toxicologic Emergencies* 1299- 1307. McGraw Hill.
5. Howland, MA. (2011) *Succimer.* *Goldfrank's Toxicologic Emergencies* 1284-1289. McGraw Hill.

# UPSTATE

MEDICAL UNIVERSITY

Upstate NY Poison Center

750 East Adams Street

Syracuse, NY 13210