

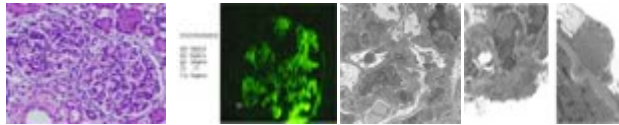
Getting Over the Hump

A 26 year-old man with no past medical problems was in good health until about one week ago when he had a sore throat. He was given an antibiotic at an urgent care clinic but 3 days later began to have ankle swelling. On evaluation now he has fever (38.2 C), BP 134/64 mm Hg, HR 76/min, normal JVP, mild pitting ankle edema, no rash, lungs clear, proteinuria (2+; urine protein/creatinine ratio 0.27), hematuria (3+; 25-50 RBC/HPF), renal insufficiency (serum creatinine 1.7 mg/dl), hypocomplementemia (low C3 at 23 mg/dl [90-180] and normal C4 at 30 mg/dl [10-40])

1. Summarize the renal presentation (select from **List 1**).

A renal biopsy was performed.

Pathology Report for Biopsy



Slide 1 Slide 2 Slide 3 Slide 4

All of the glomeruli were similar to that shown in Slide 1. Immunofluorescence is shown in Slide 2 and electron micrographs in Slides 3-4.

2. What is the pathologic diagnosis (select from **List 2**).
3. What is the probable final clinico-pathologic diagnosis?