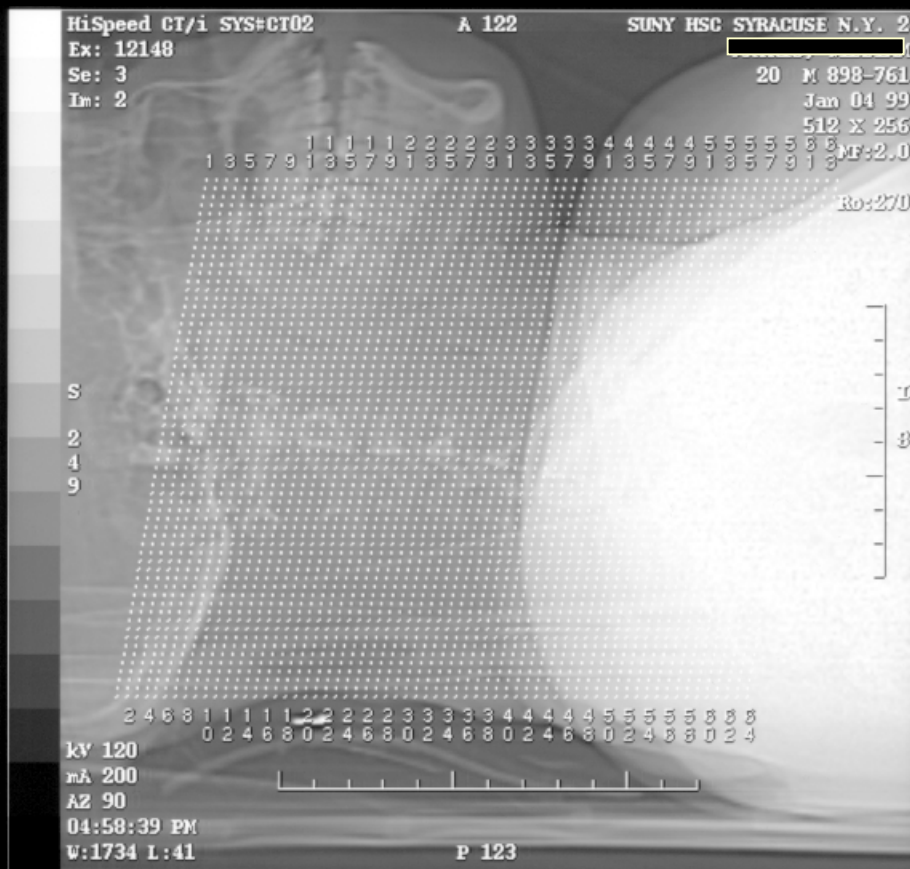
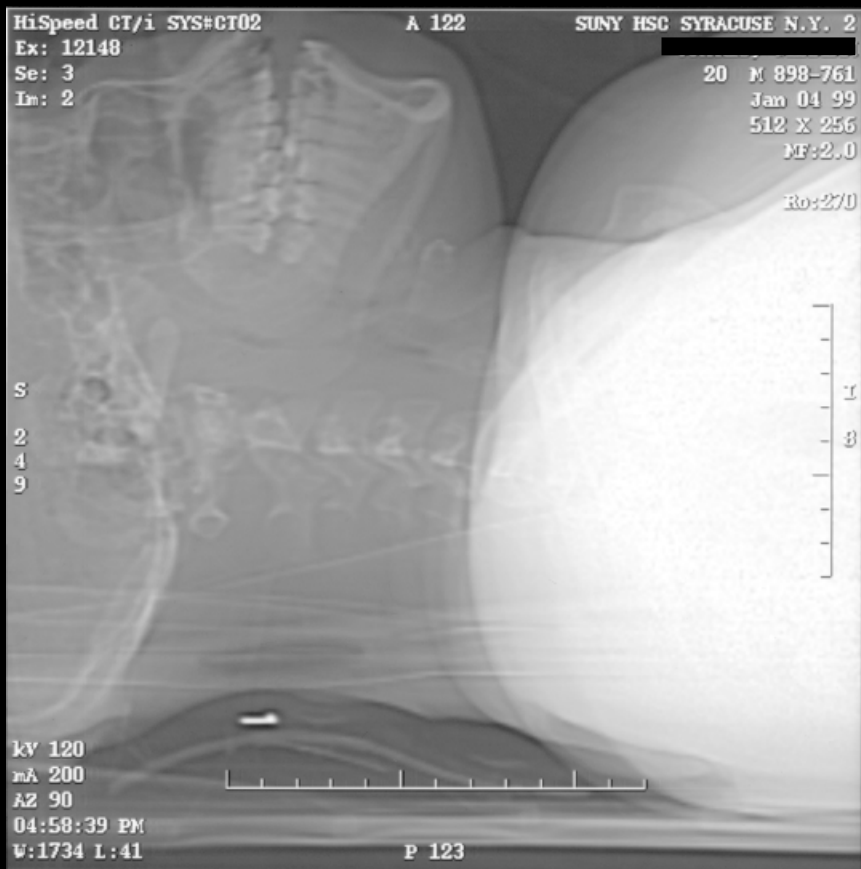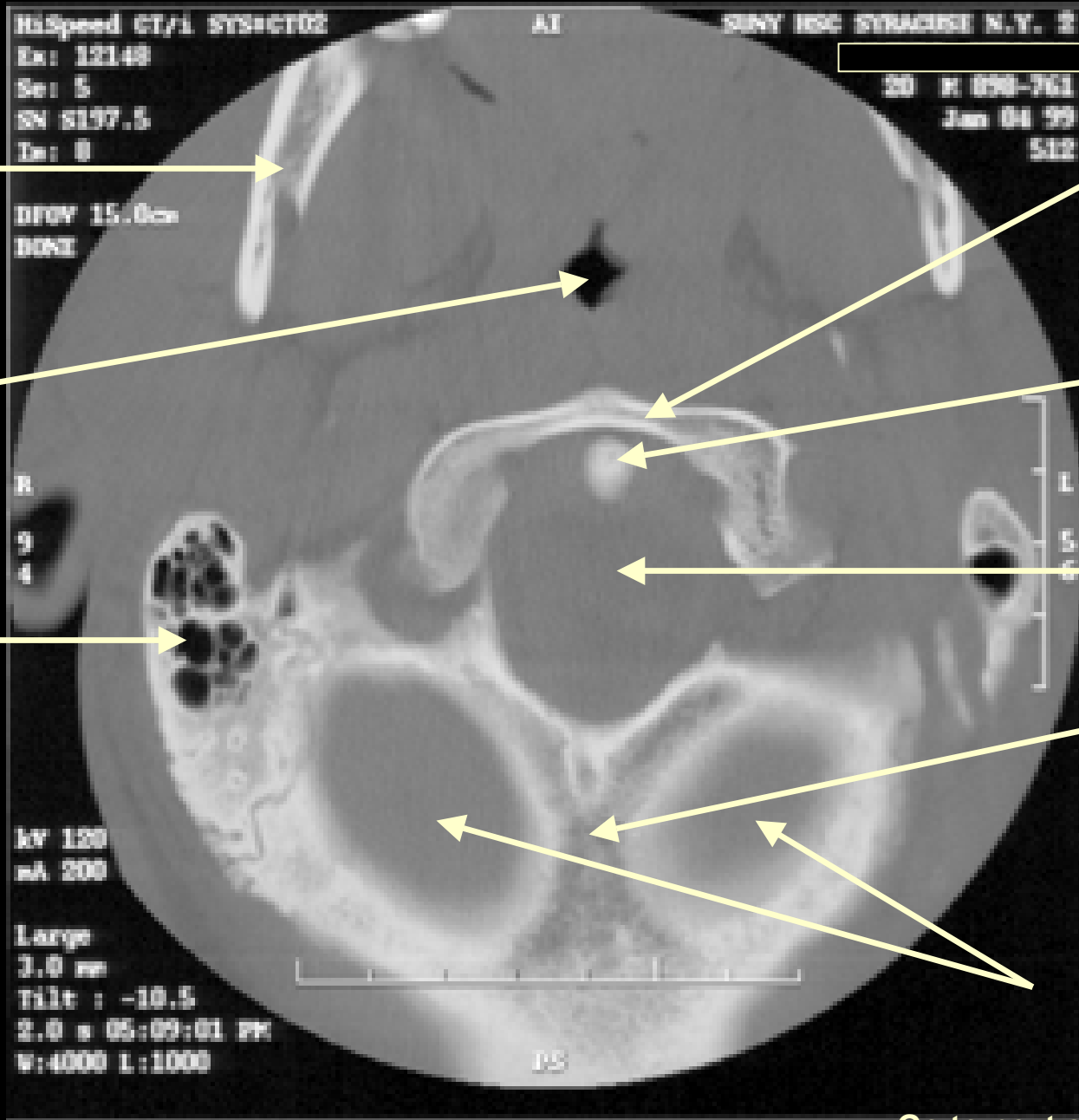


HEAD AND NECK



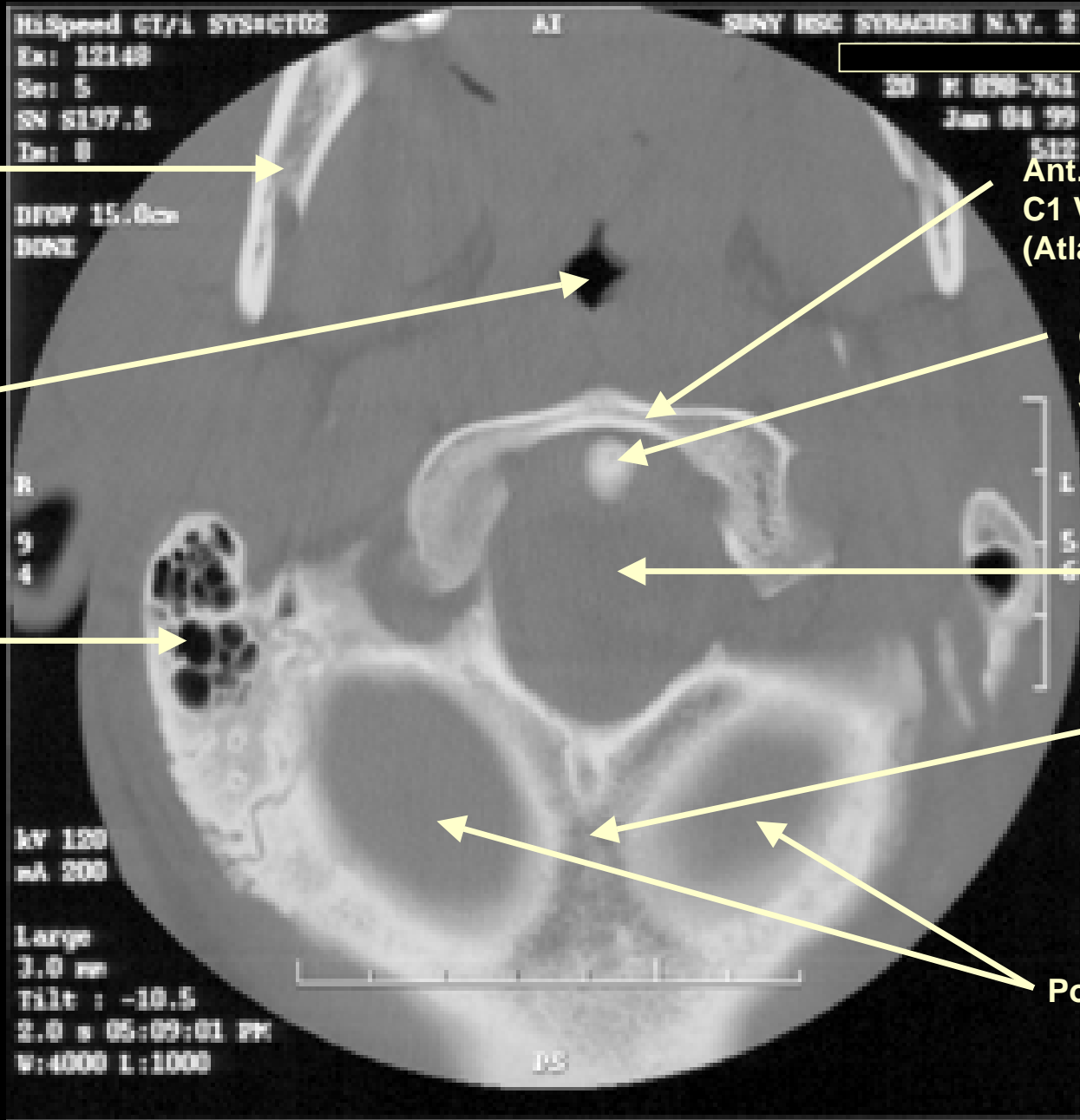
The radiographs shown above will provide landmarks and indicate the levels at which the CT scans that follow were made. They can serve as a reference tool to help you in your identification of the labeled structures.

Level 8



Go to next slide to see labels

Level 8



Ramus of Mandible




Oropharynx



Mastoid Air Cells of Temporal Bone



Ant. arch of C1 Vertebra (Atlas)



Odontoid Process (Dens) of C2 Vertebra (Axis)




Foramen Magnum



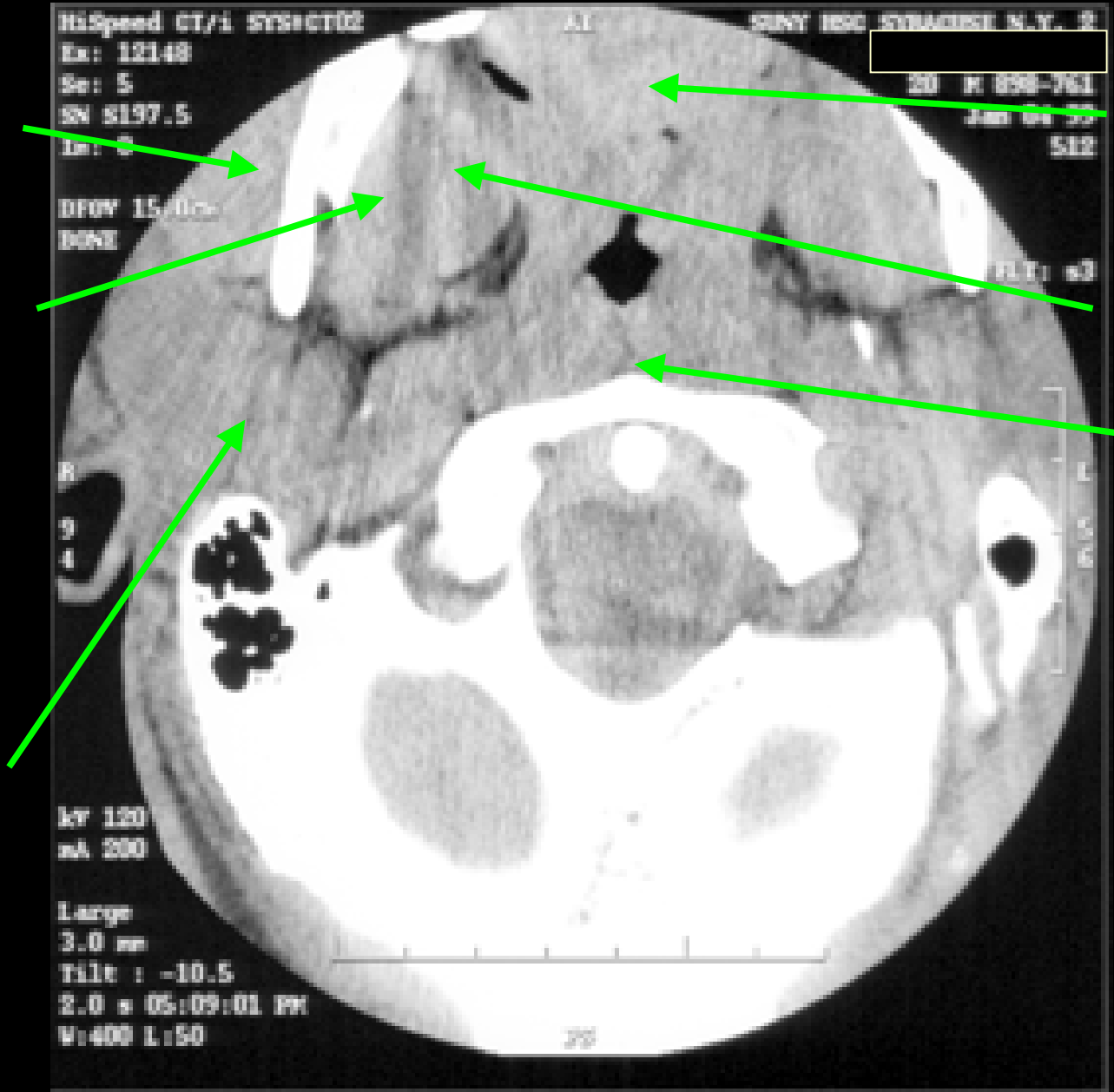
Occipital Bone



Posterior Cranial Fossa

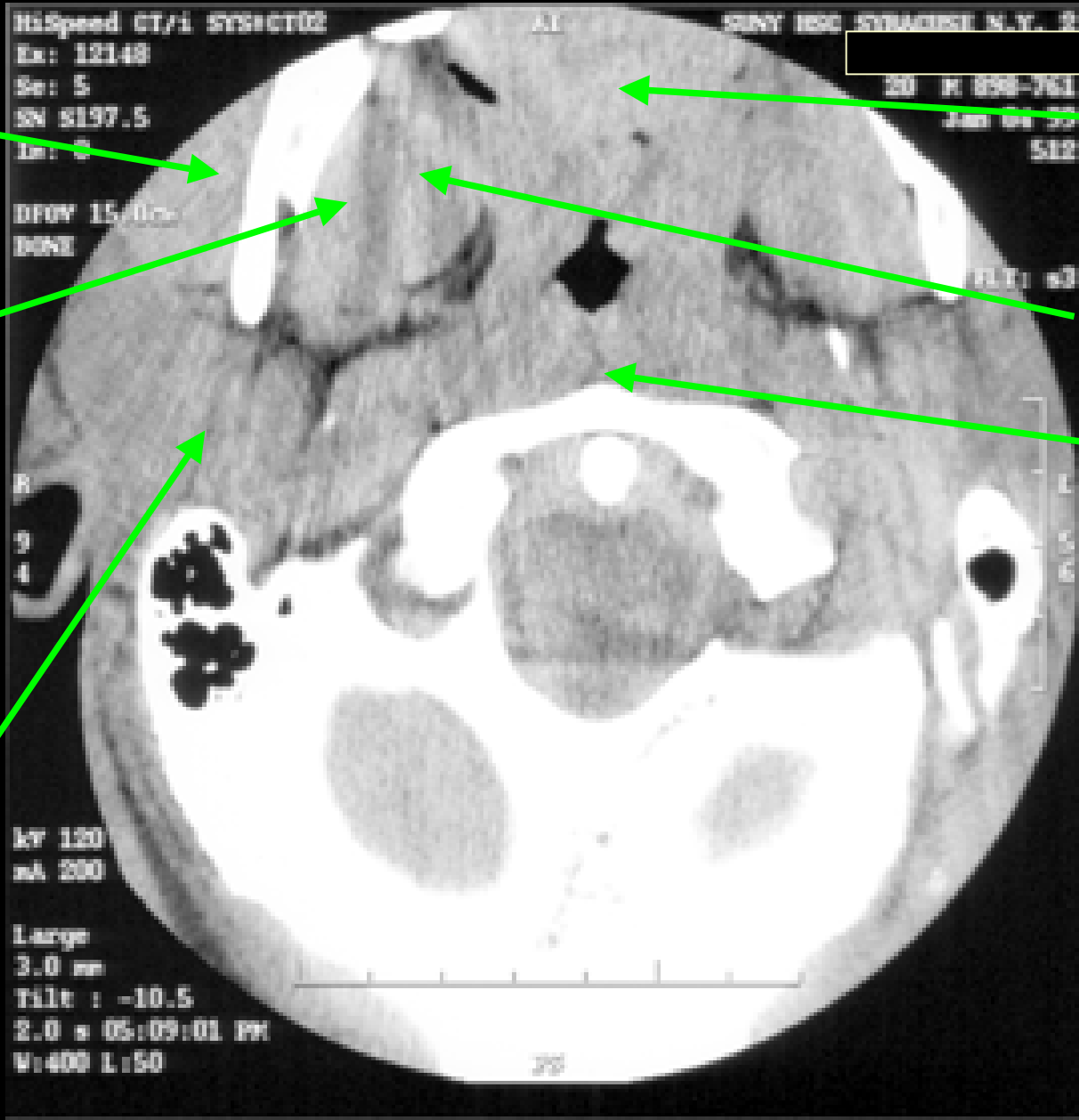


Level 8



Go to next slide to see labels

Level 8



**Masseter
Muscle**

**Lateral Pterygoid
Muscle**

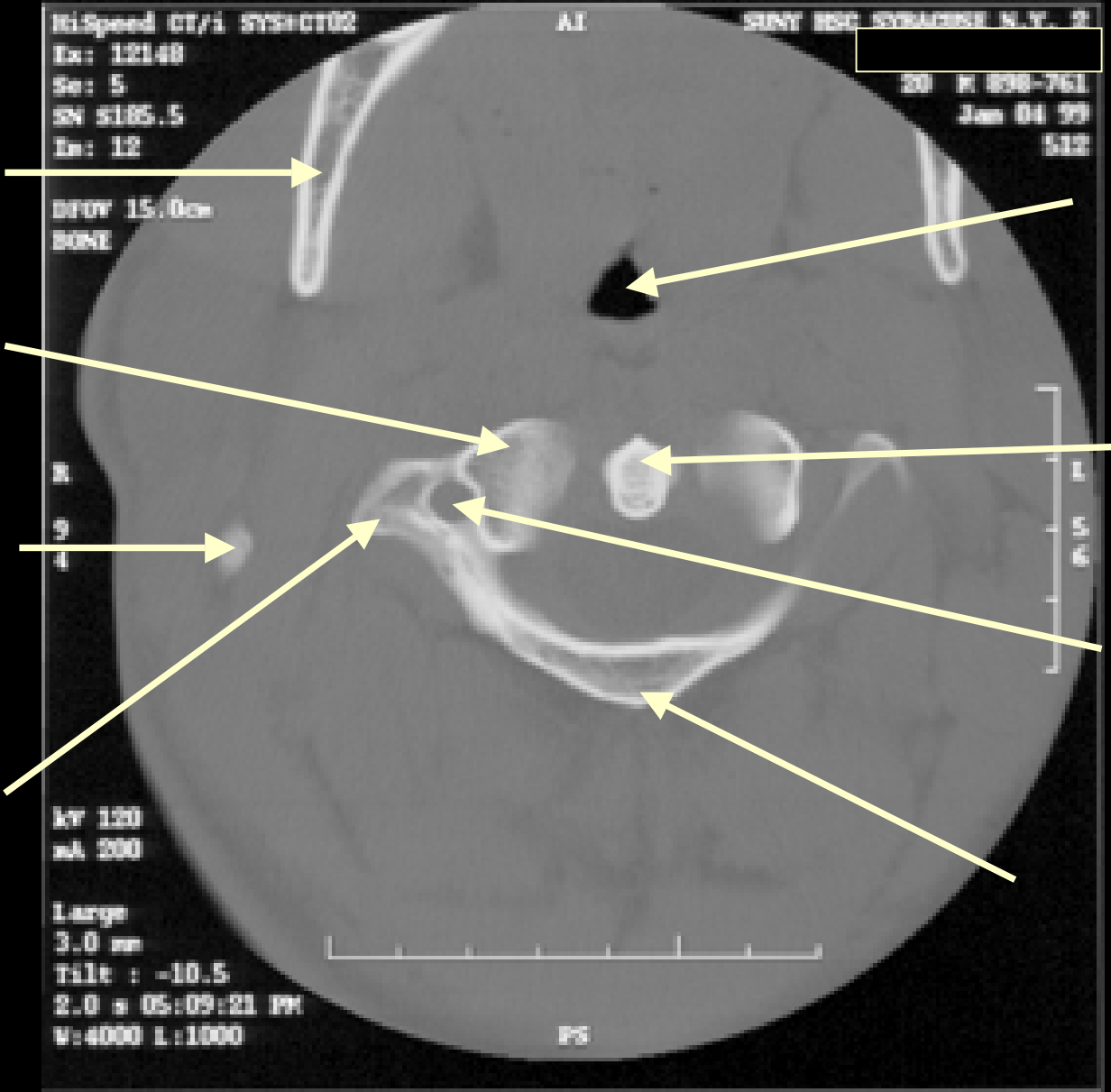
**Temporalis
Muscle**

Tongue

**Medial Pterygoid
Muscle**

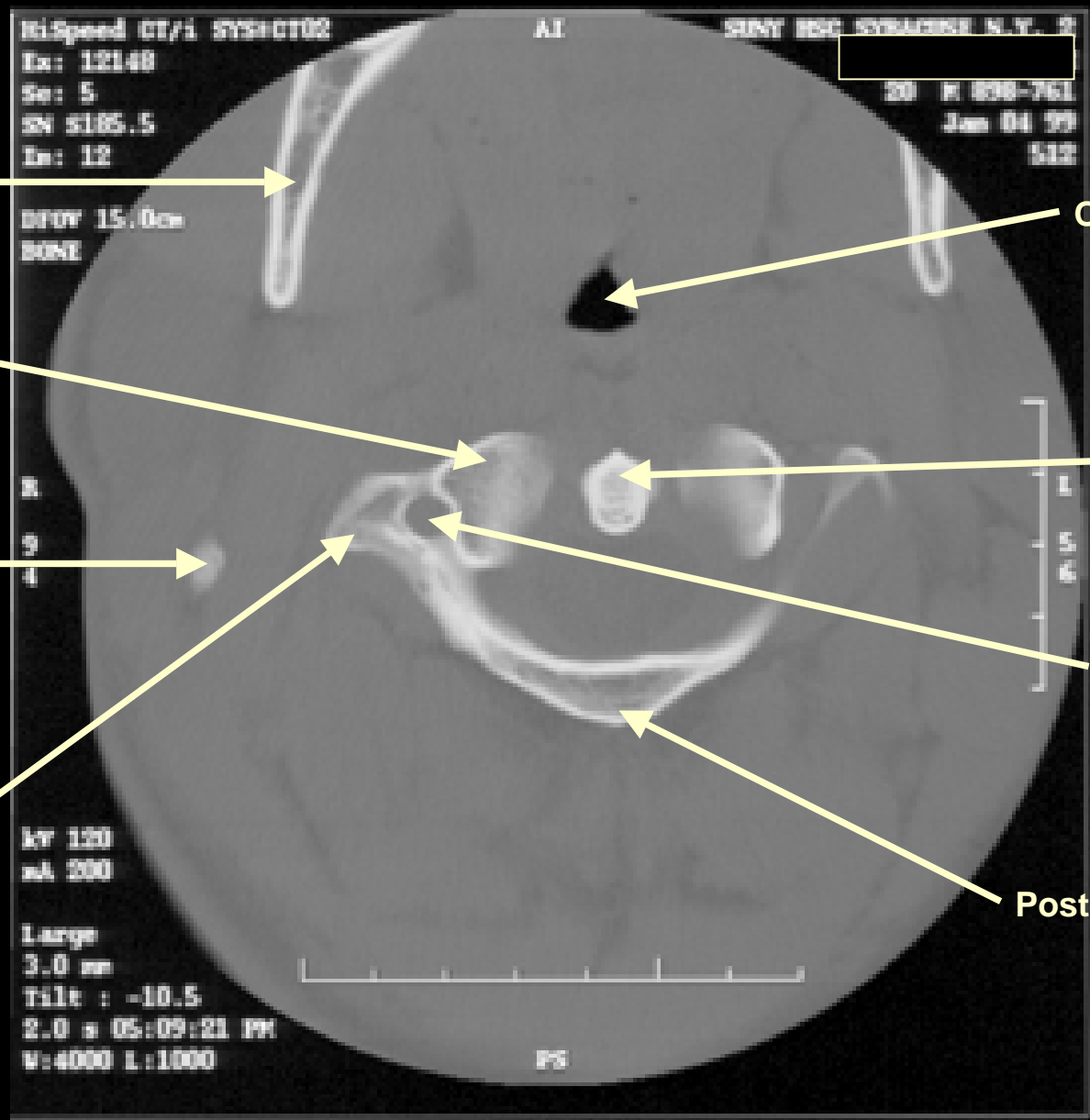
**Prevertebral
Muscles**

Level 12




Go to next slide to see labels

Level 12



Ramus of Mandible



Oropharynx



Inferior Articular Facet of C1



Odontoid Process (Dens) of C2




Mastoid Process



Transverse Foramen



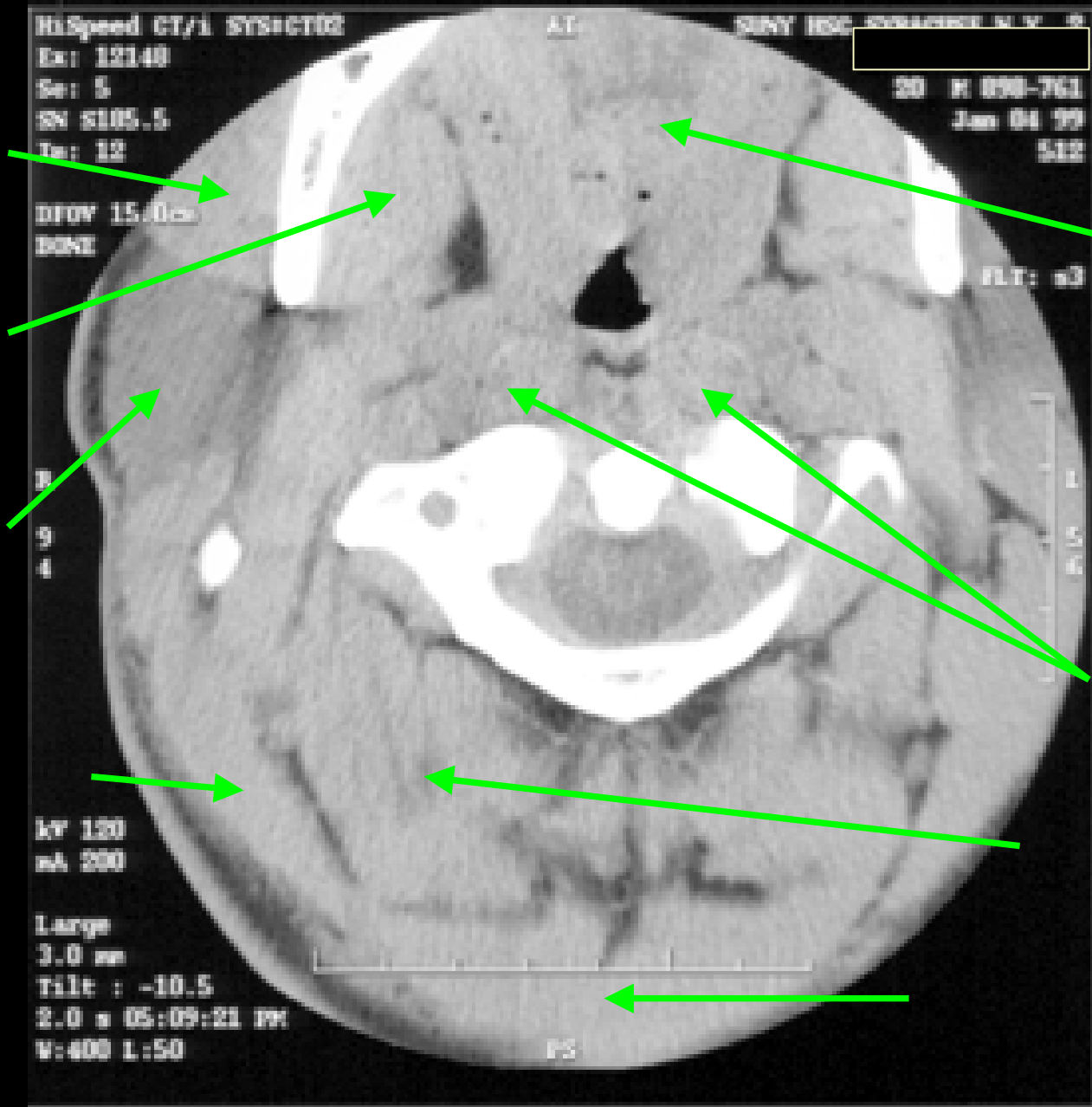
Transverse Process



Posterior Arch of C2

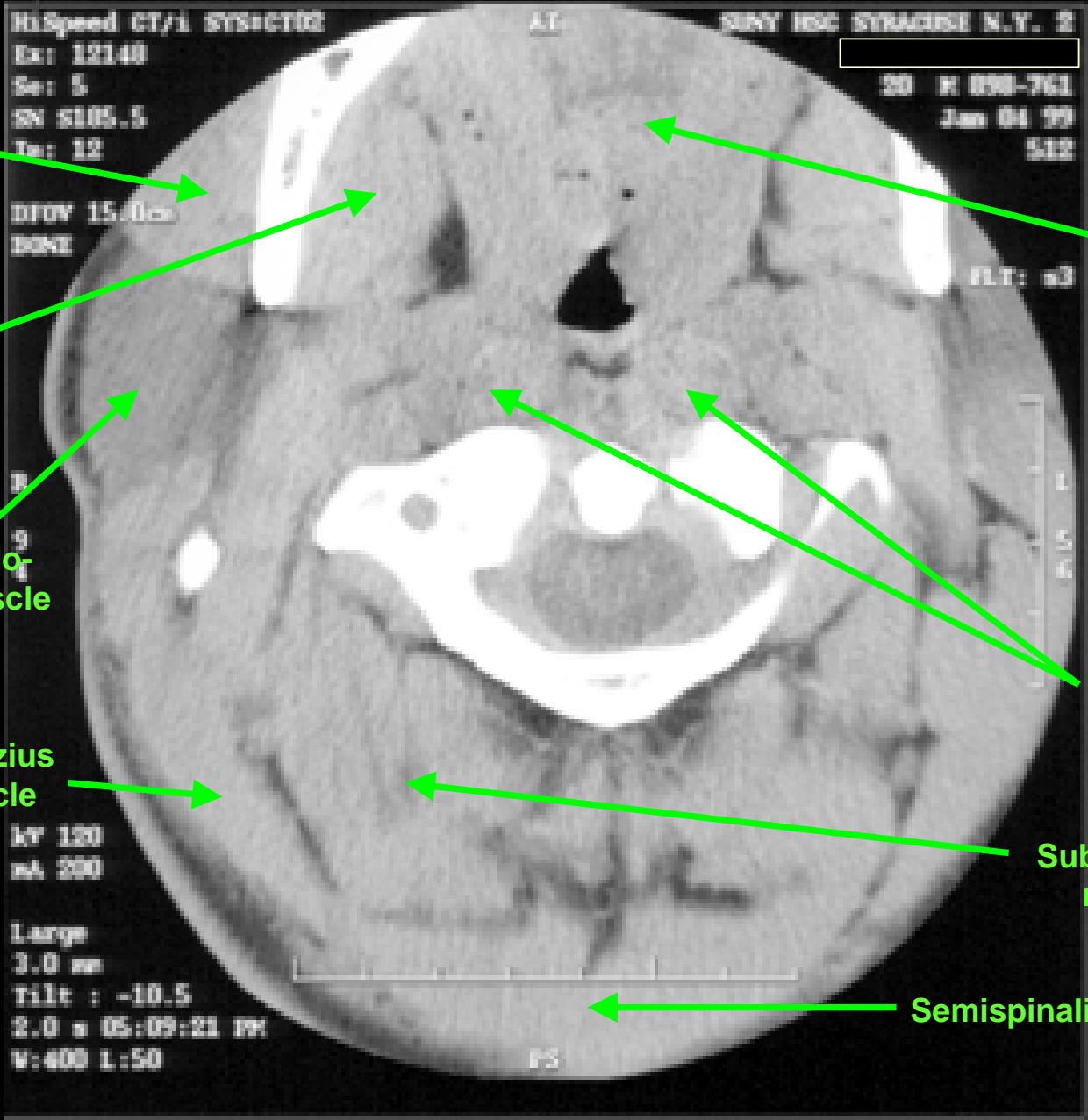


Level 12



Go to next slide to see labels

Level 12



Masseter muscle

Pterygoid muscles

Sternocleidomastoid muscle

Trapezius muscle

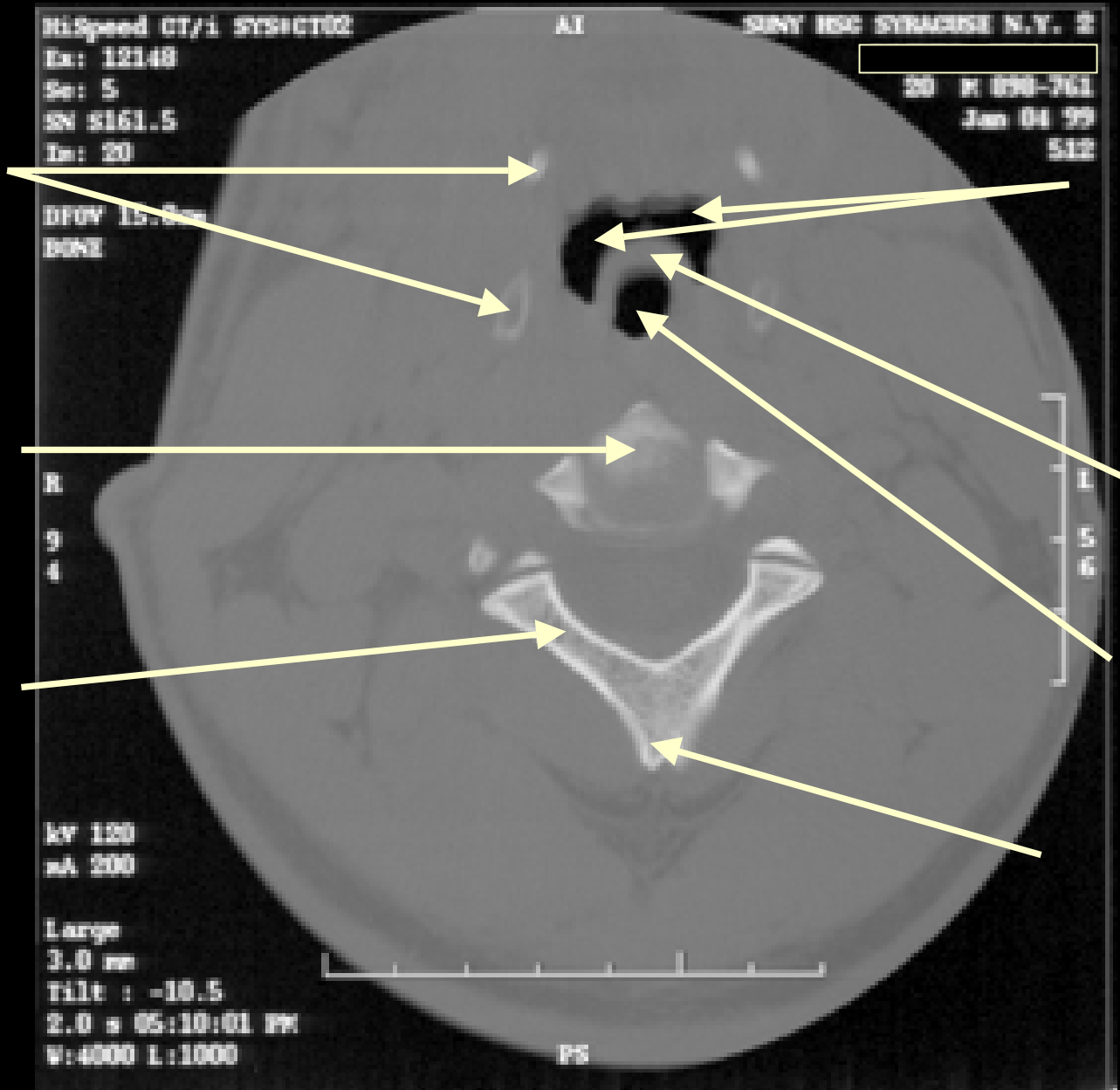
Tongue

Prevertebral muscles

Sub-Occipital muscle

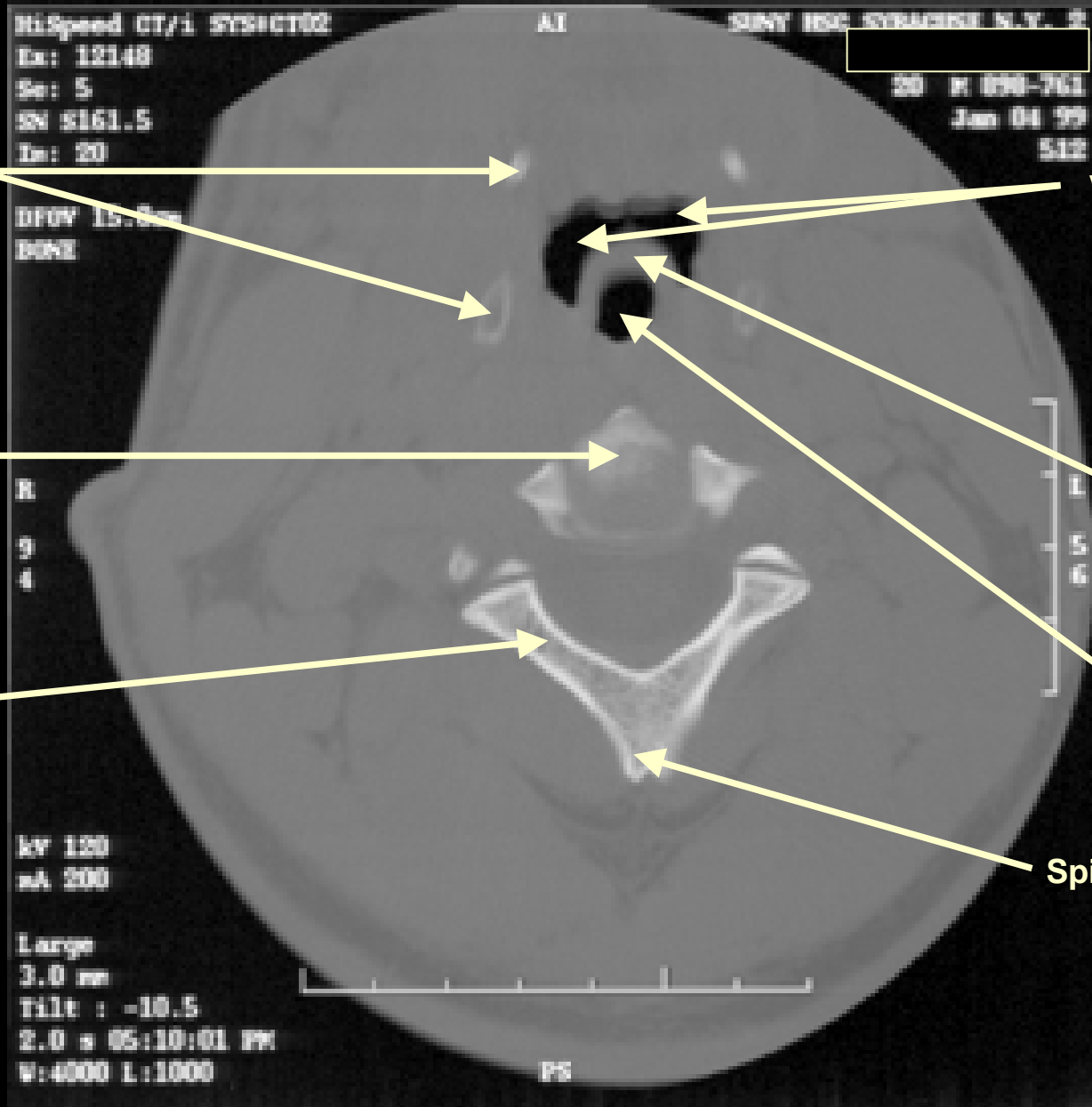
Semispinalis muscles

Level 20



Go to next slide to see labels

Level 20



Hyoid Bone



Vallecula of Larynx



Body of C2



Epiglottis



Lamina of C2



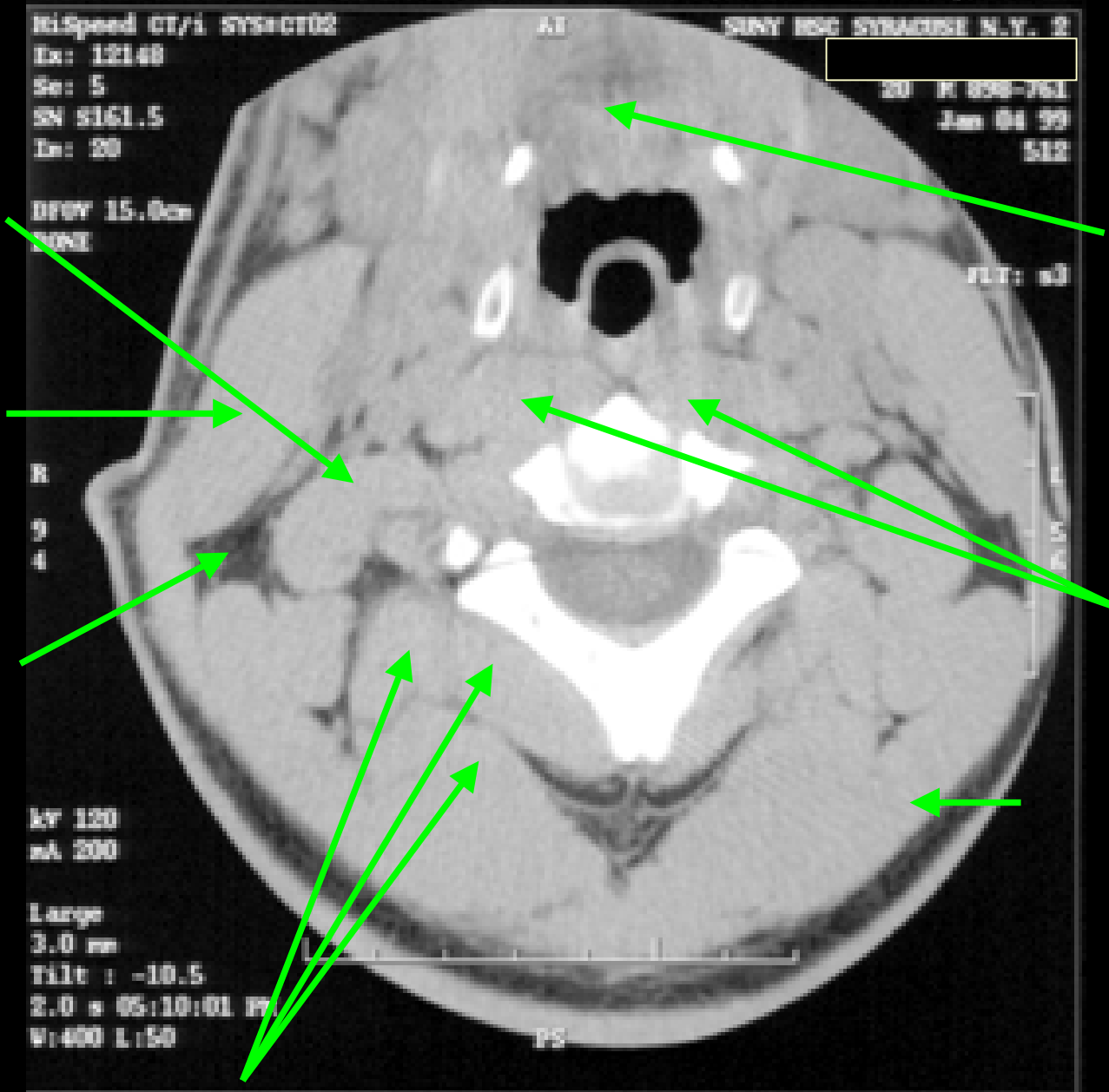
Hypopharynx (Laryngopharynx)



Spinous Process of C2

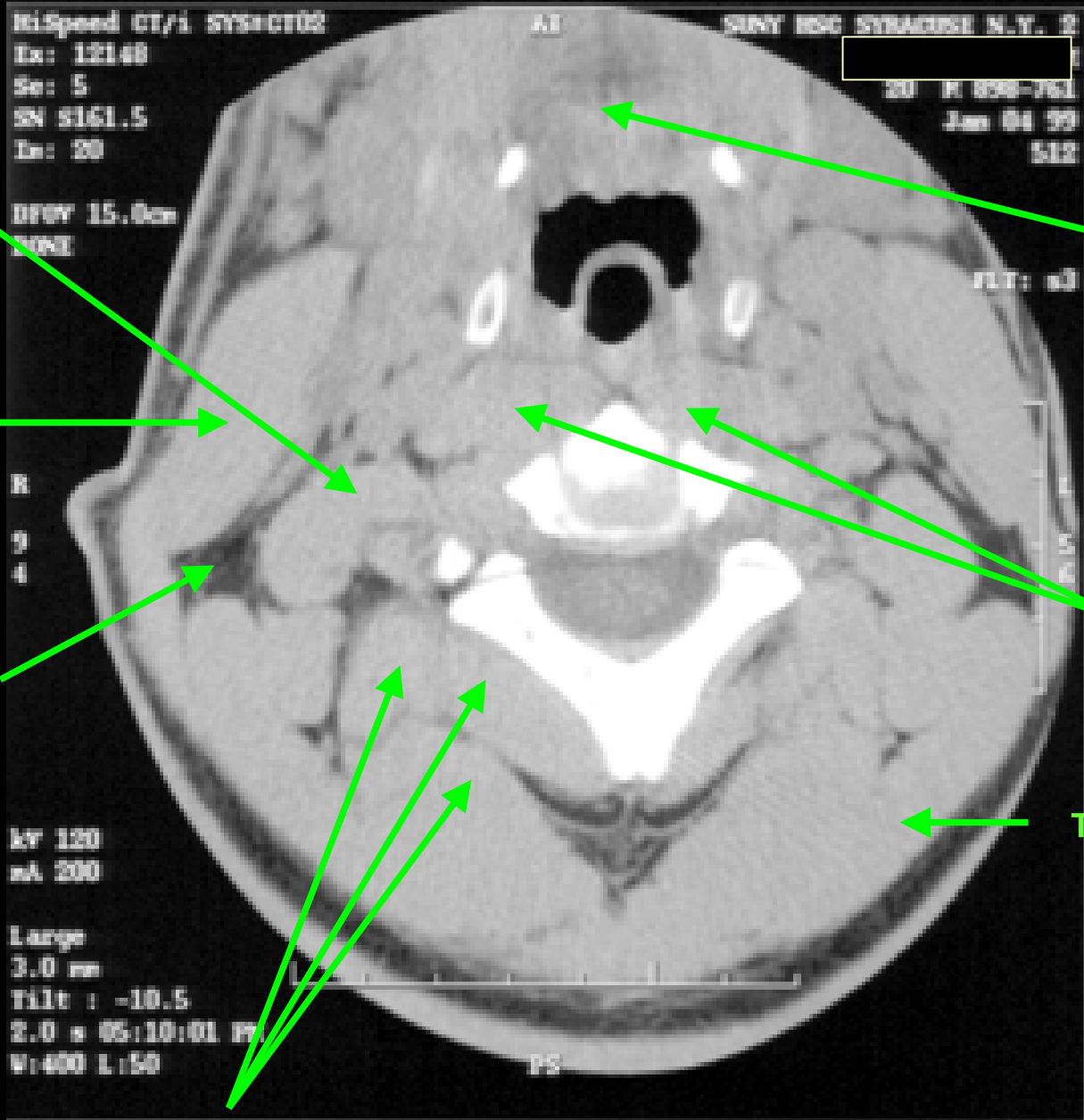


Level 20



Go to next slide to see labels

Level 20



Scalene muscle

SCM

Carotid Sheath

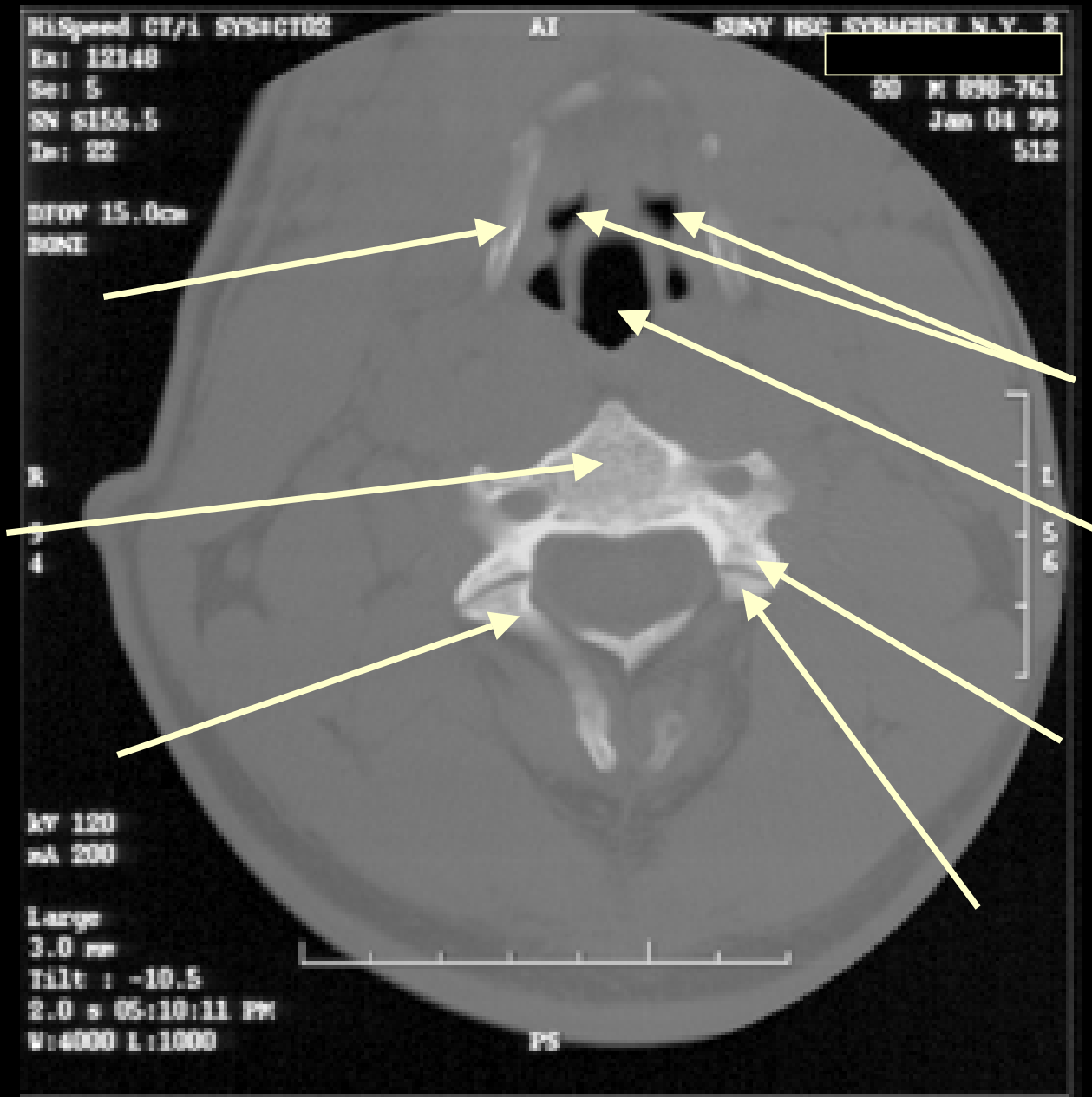
Sub-Occipital muscles

Tongue

Prevertebral muscles

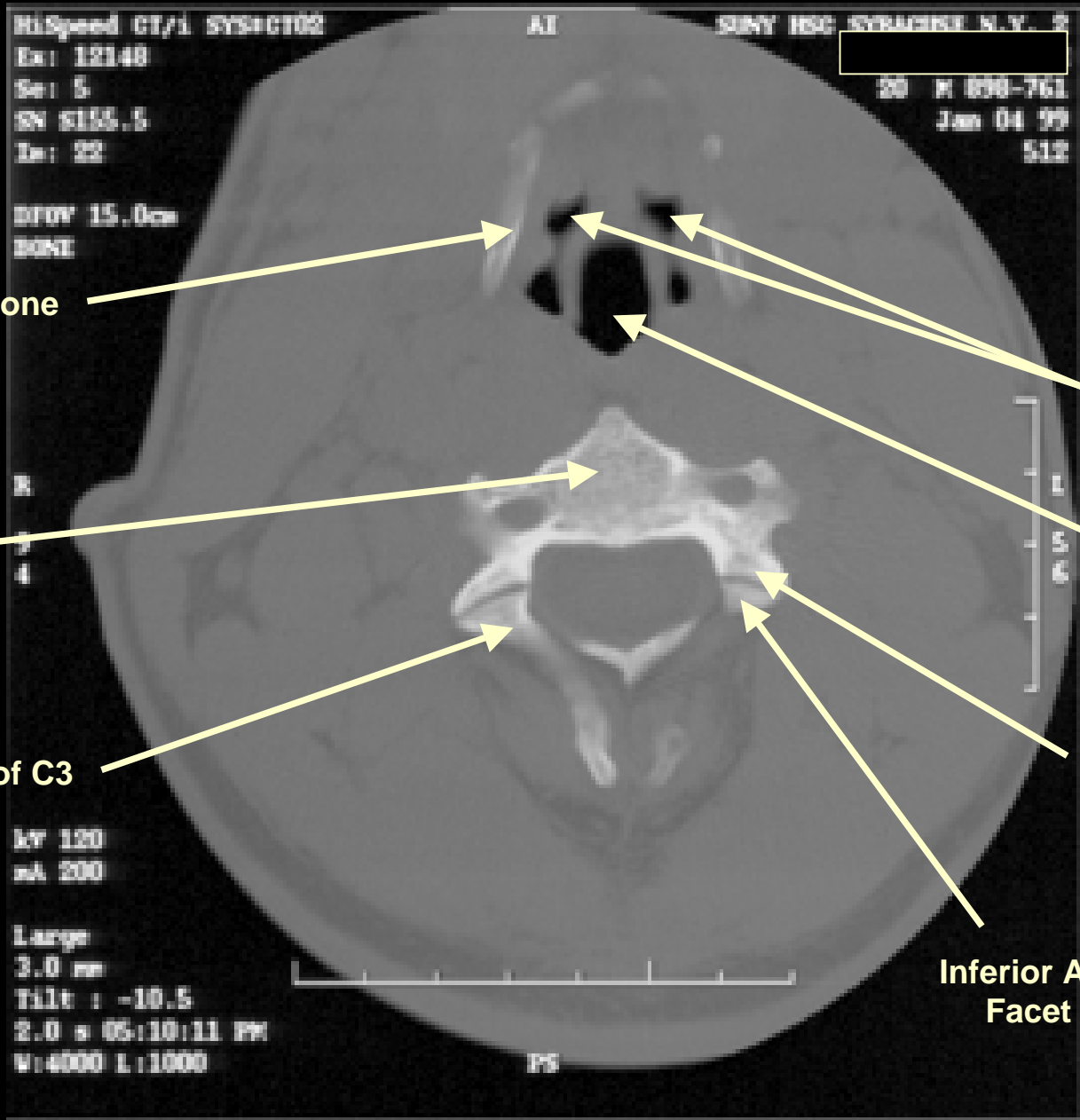
Trapezius muscle

Level 22

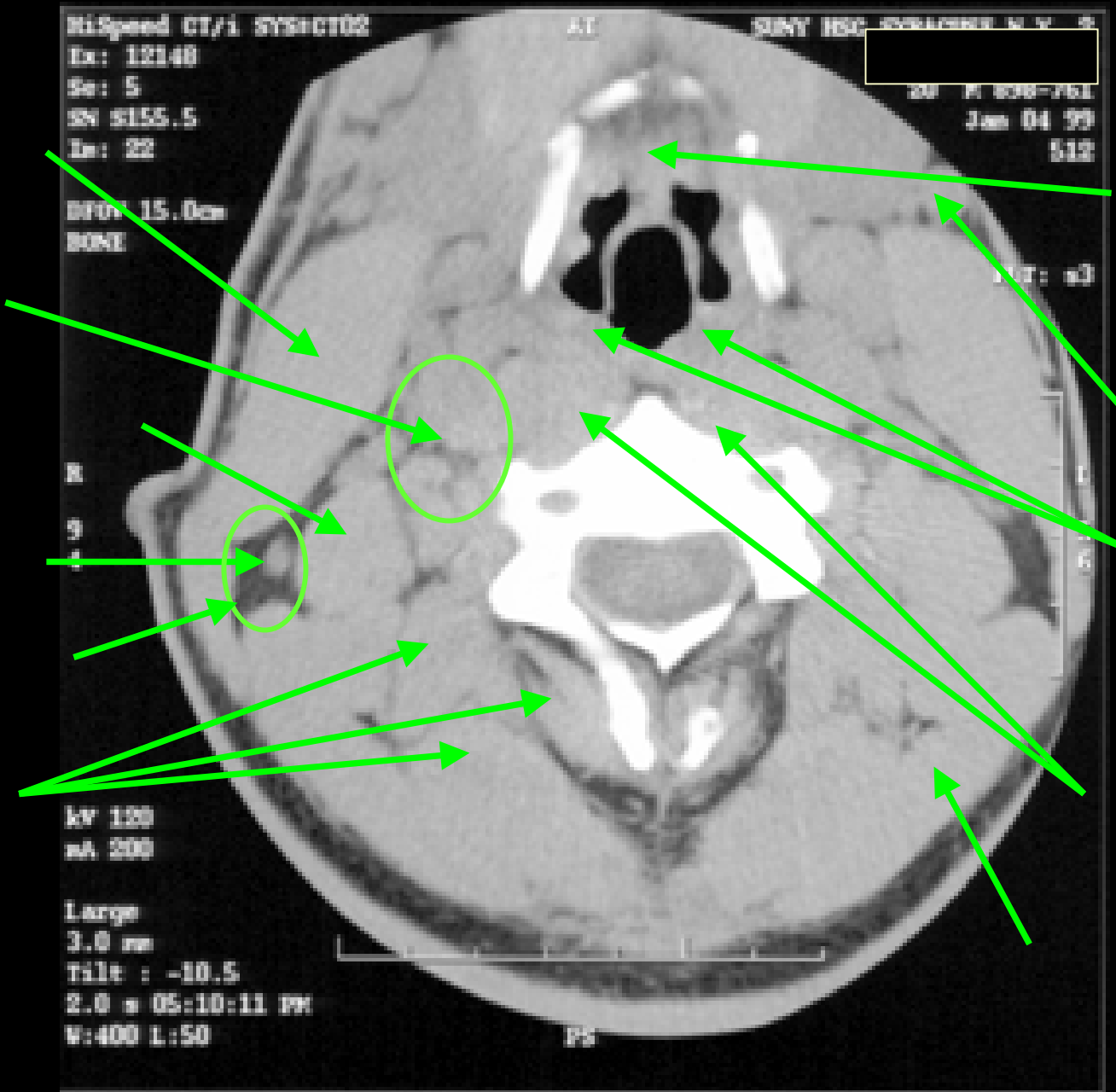


Go to next slide to see labels

Level 22

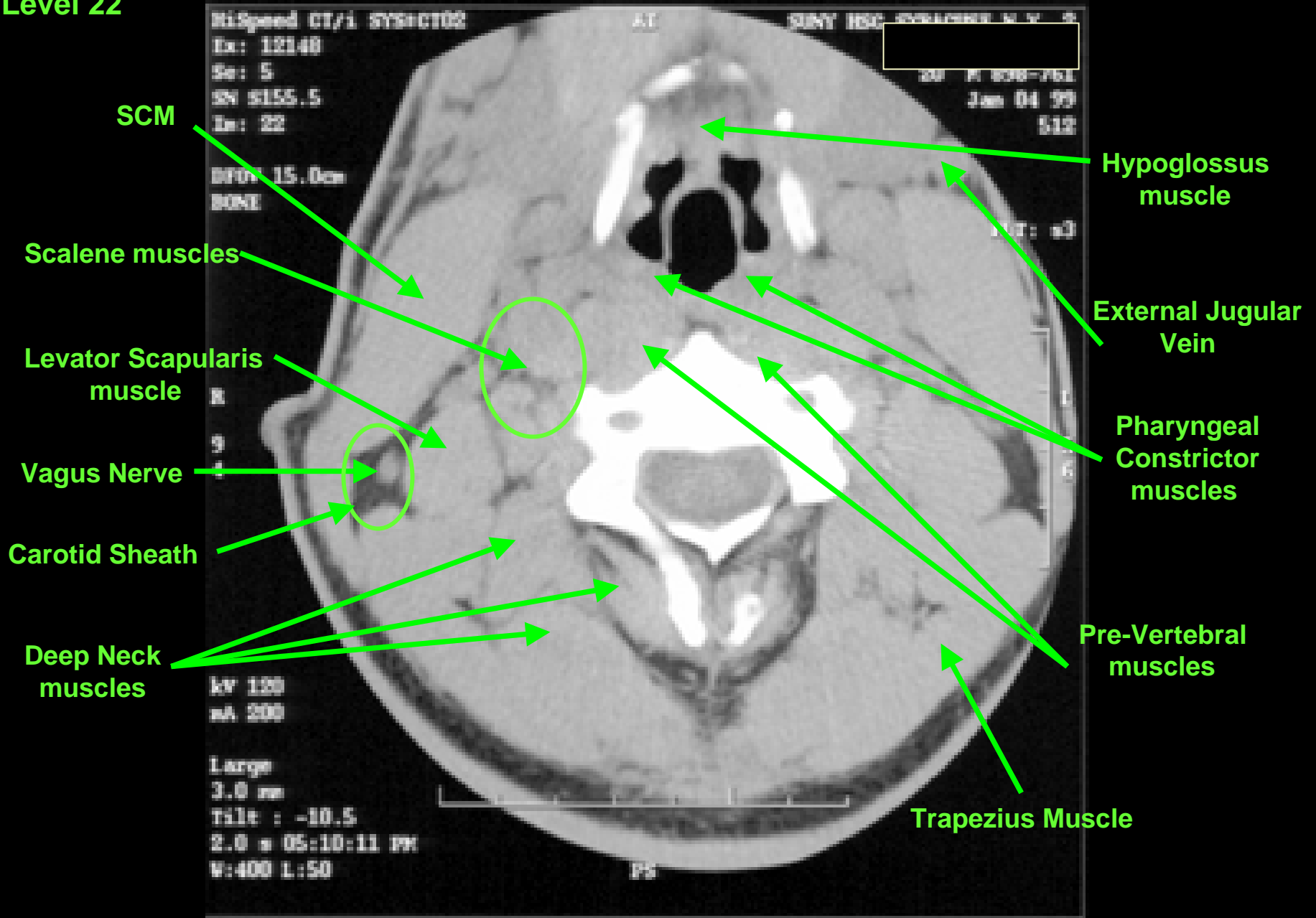


Level 22

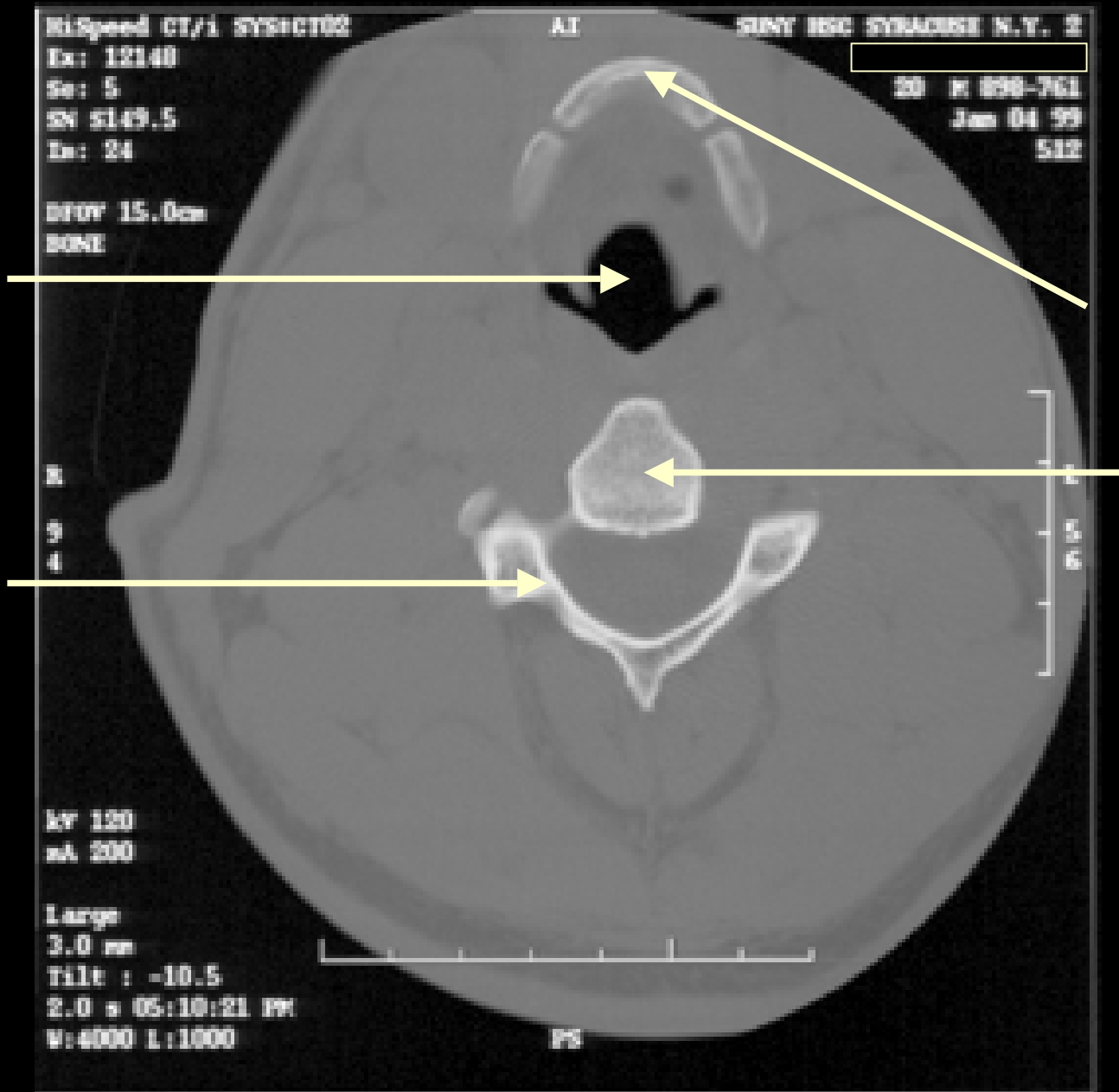

Go to next slide to see labels

Level 22

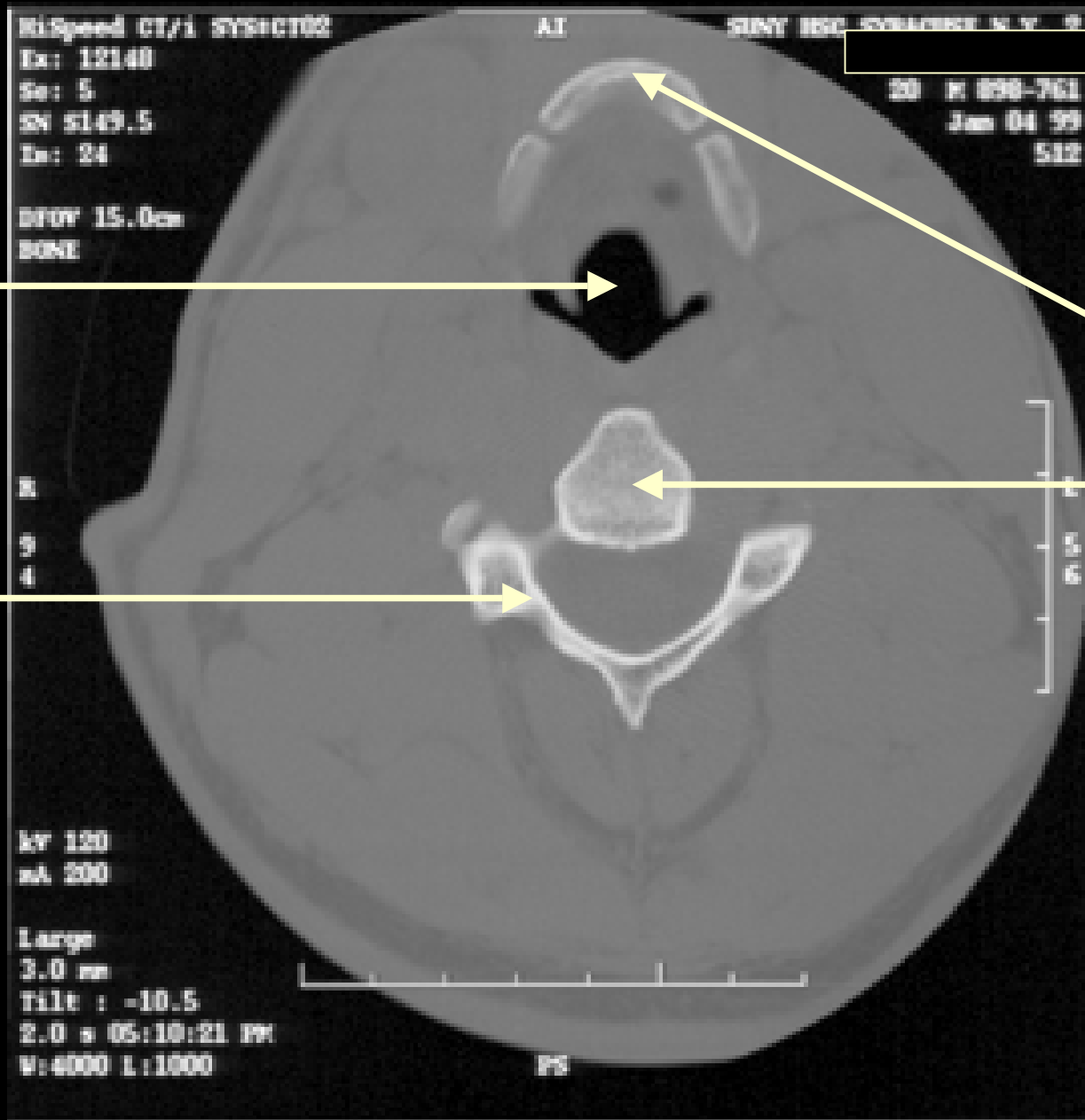

Level 24



Go to next slide to see labels

Level 24



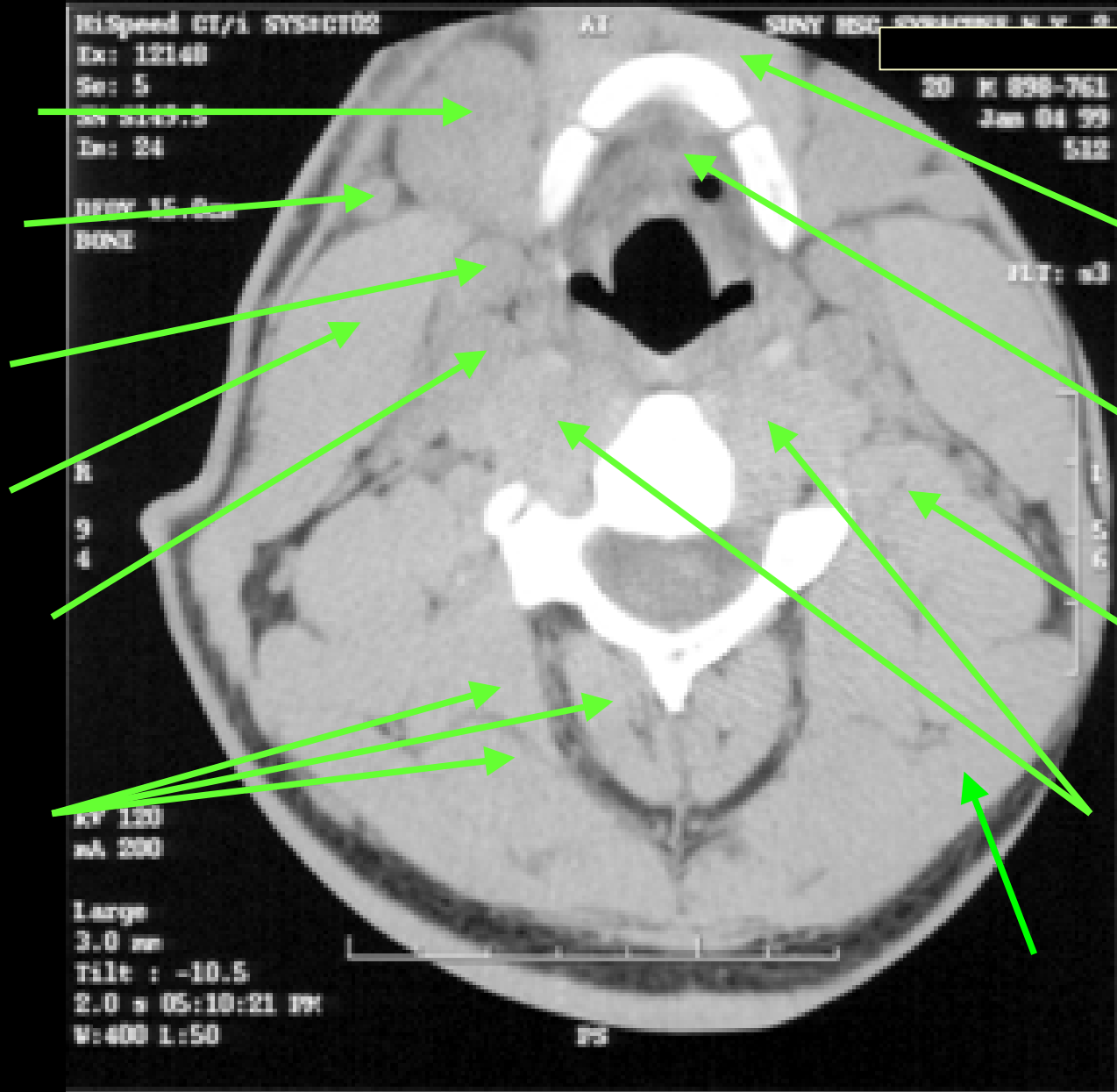Hypopharynx

Hyoid bone

Body of C3

**Lamina of
C3**

Level 24



Level 24

Submandibular Gland

External Jugular Vein

Internal Carotid Artery

SCM

Internal Jugular Vein

Deep Neck muscles

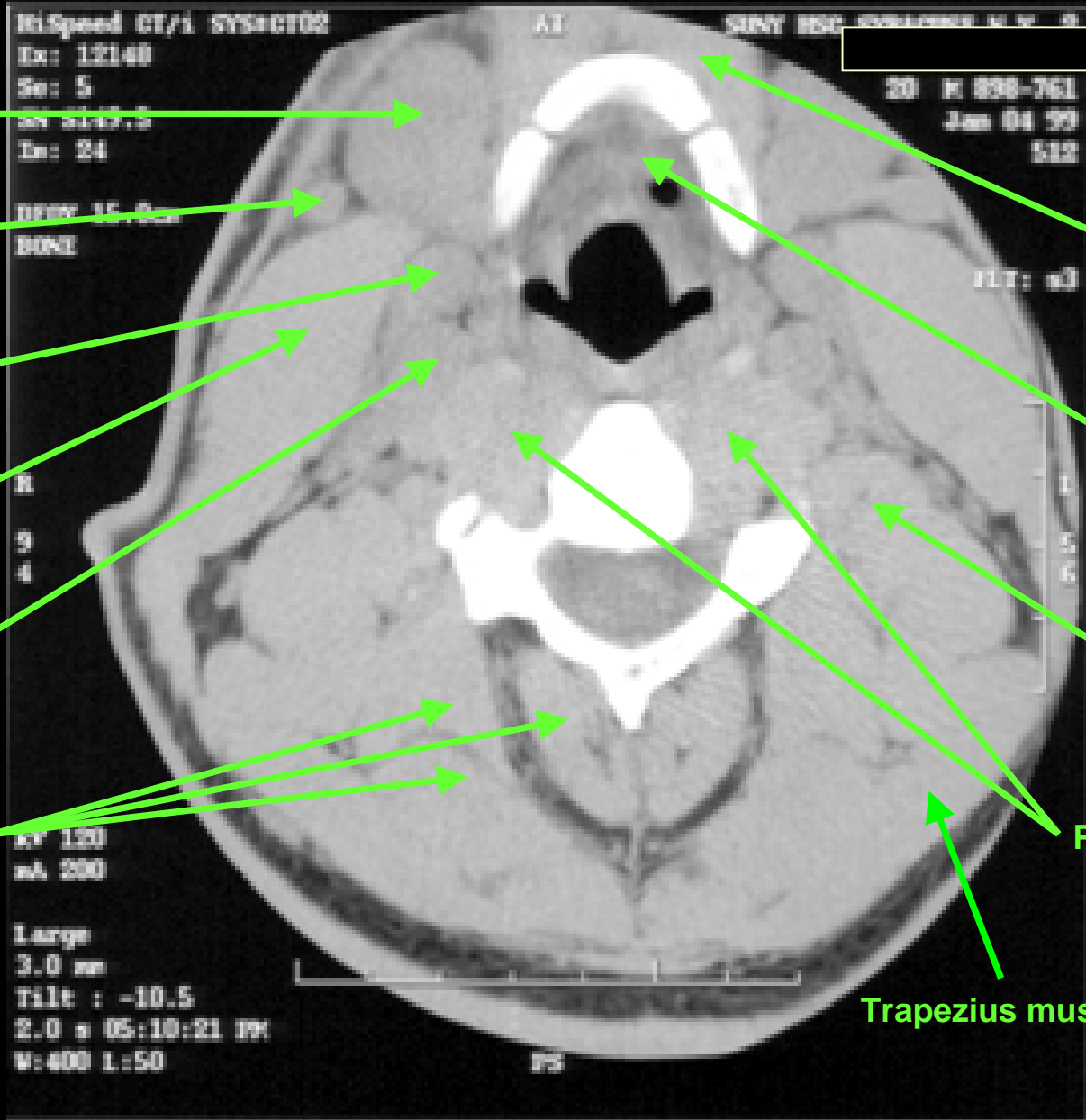
Trapezius muscle

Infrahyoid Muscles

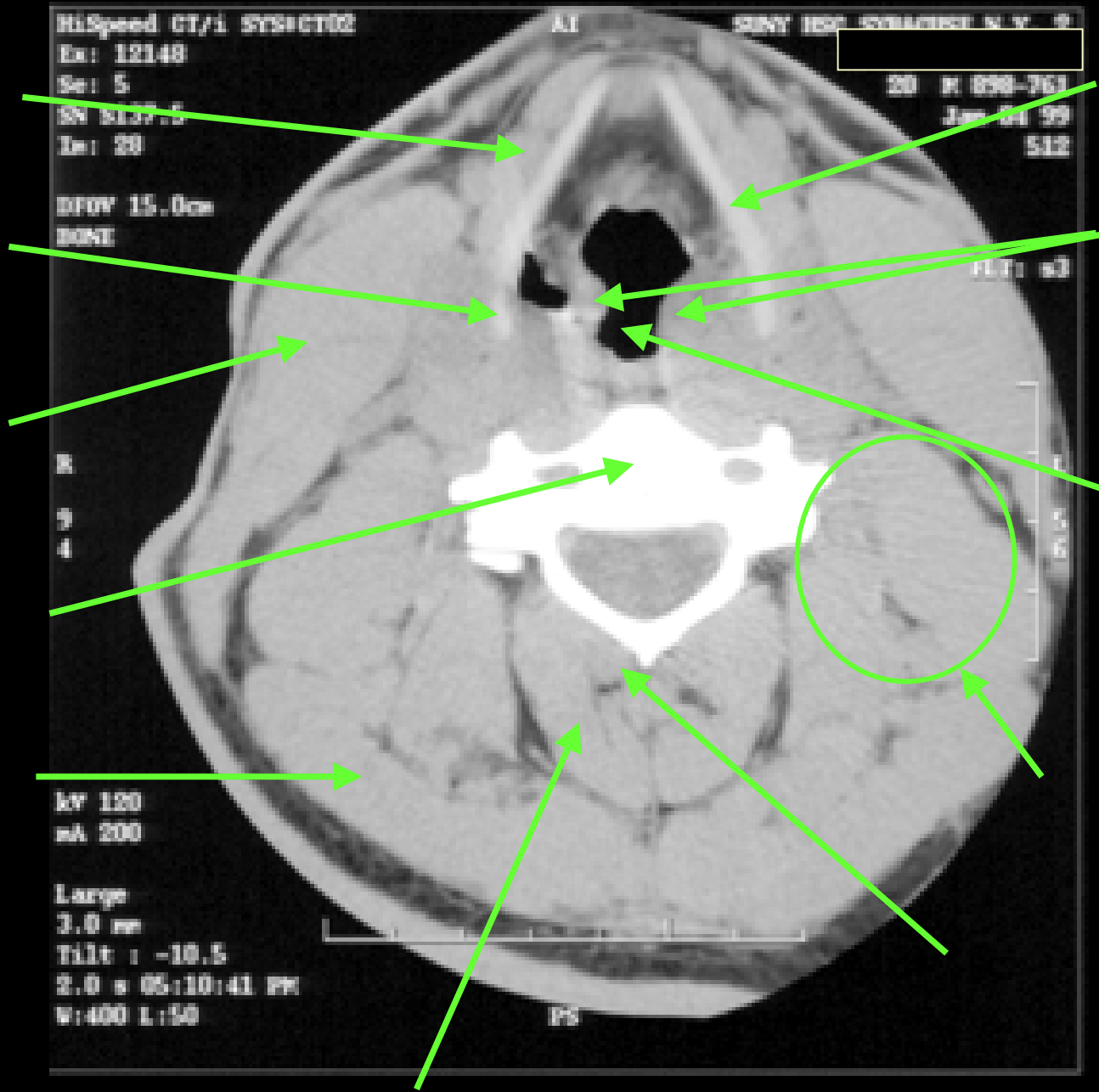
Hypoglossus muscle

Scalene muscles

Pre-Vertebral muscles

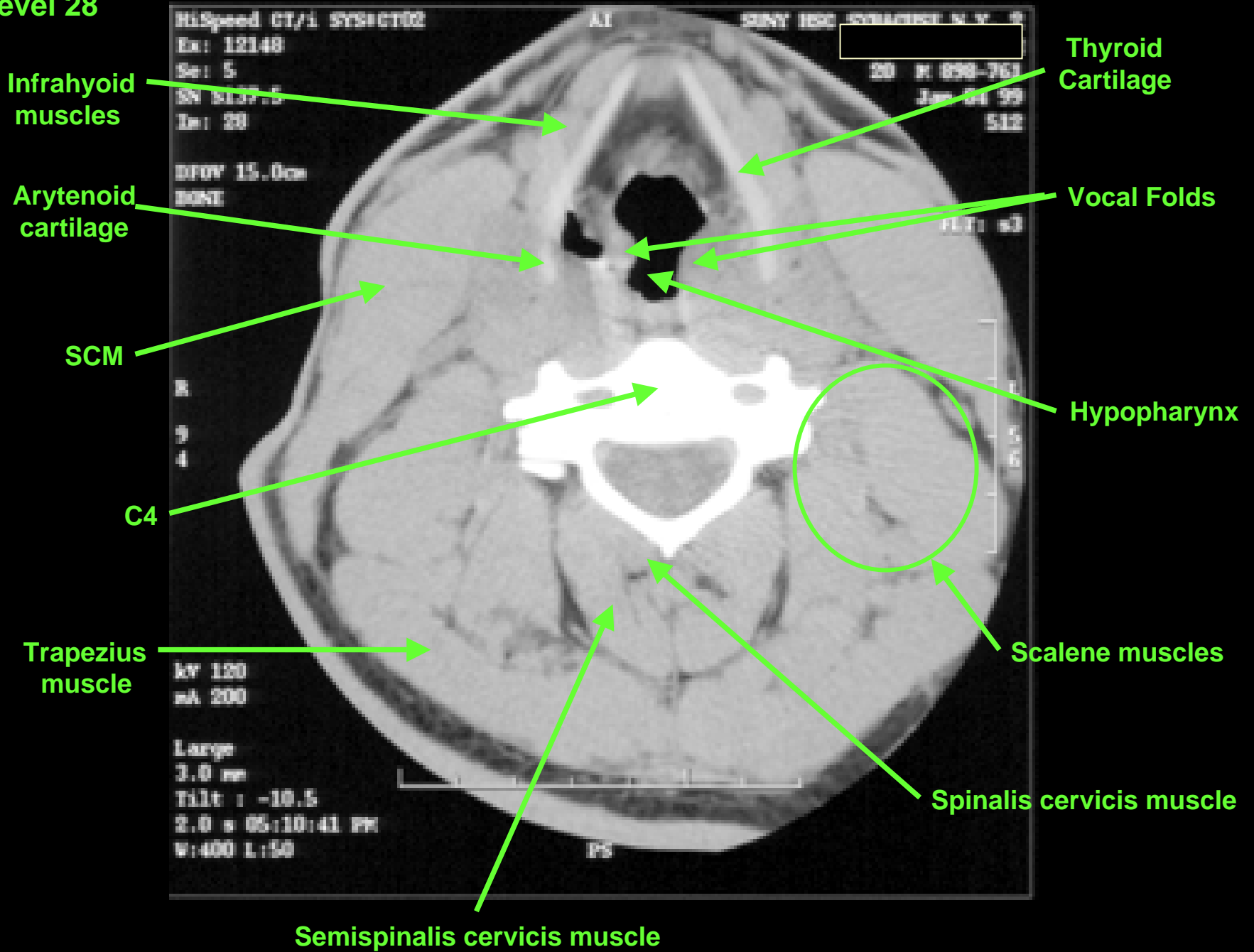


Level 28

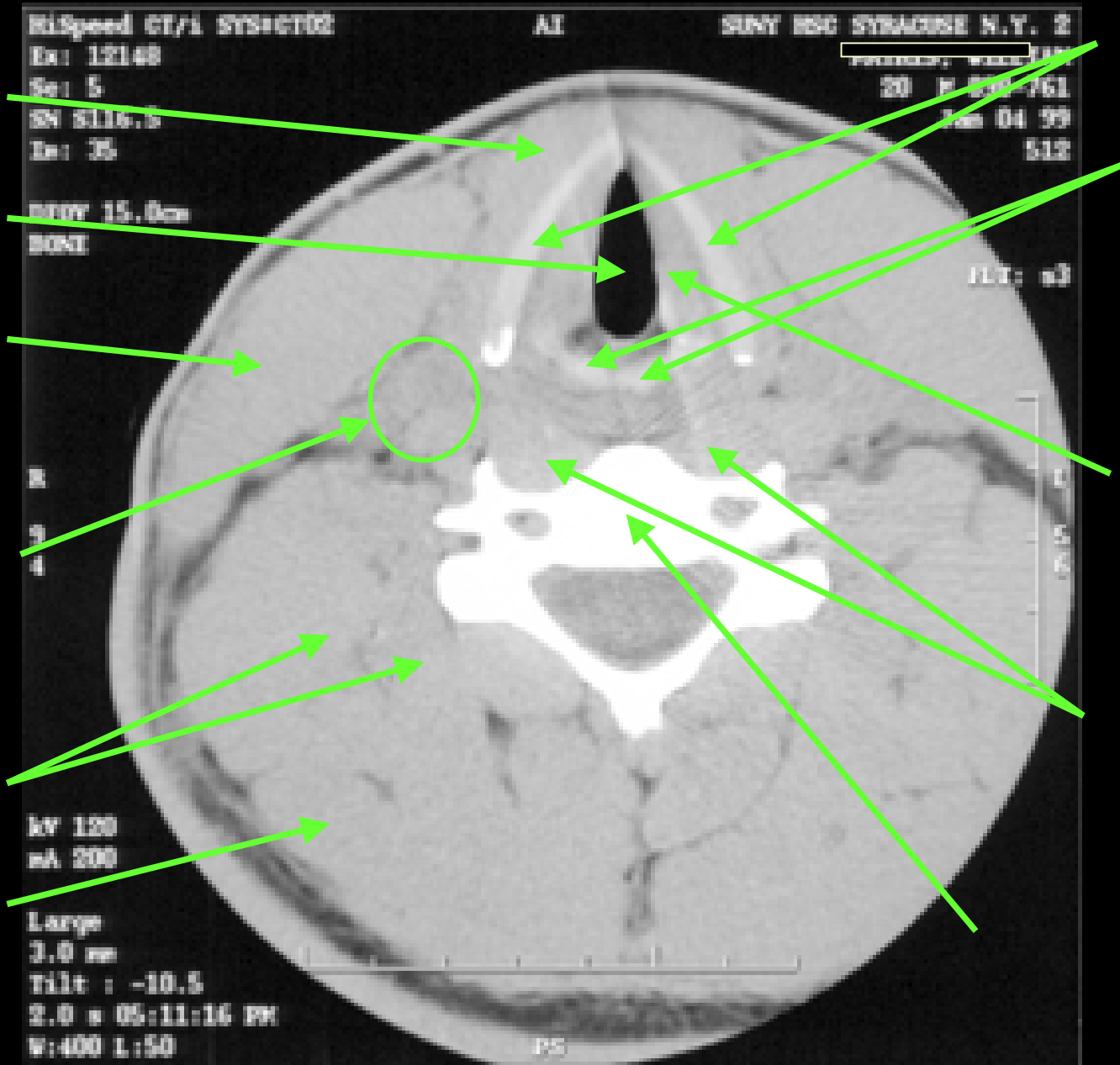


Go to next slide to see labels

Level 28

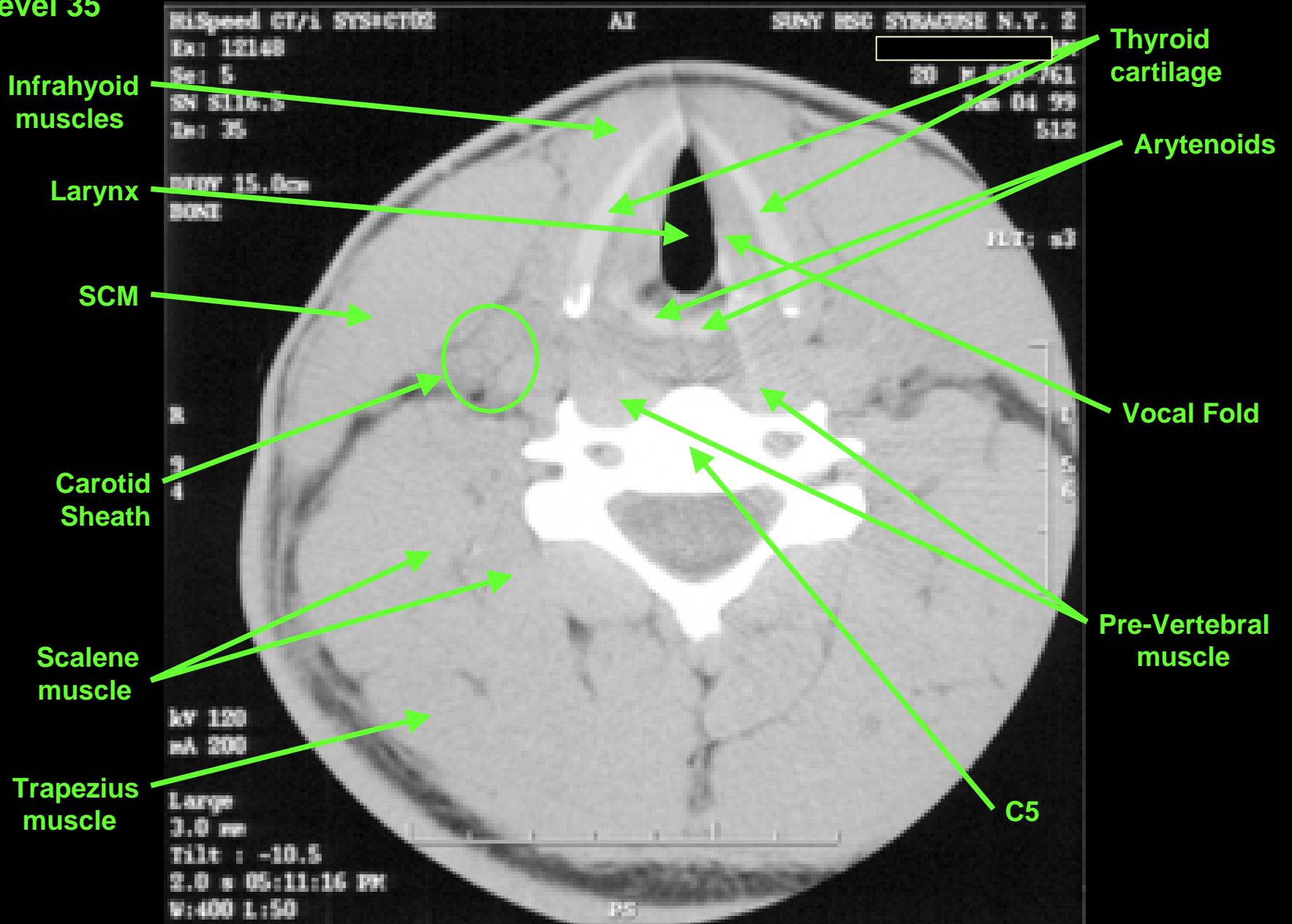


Level 35

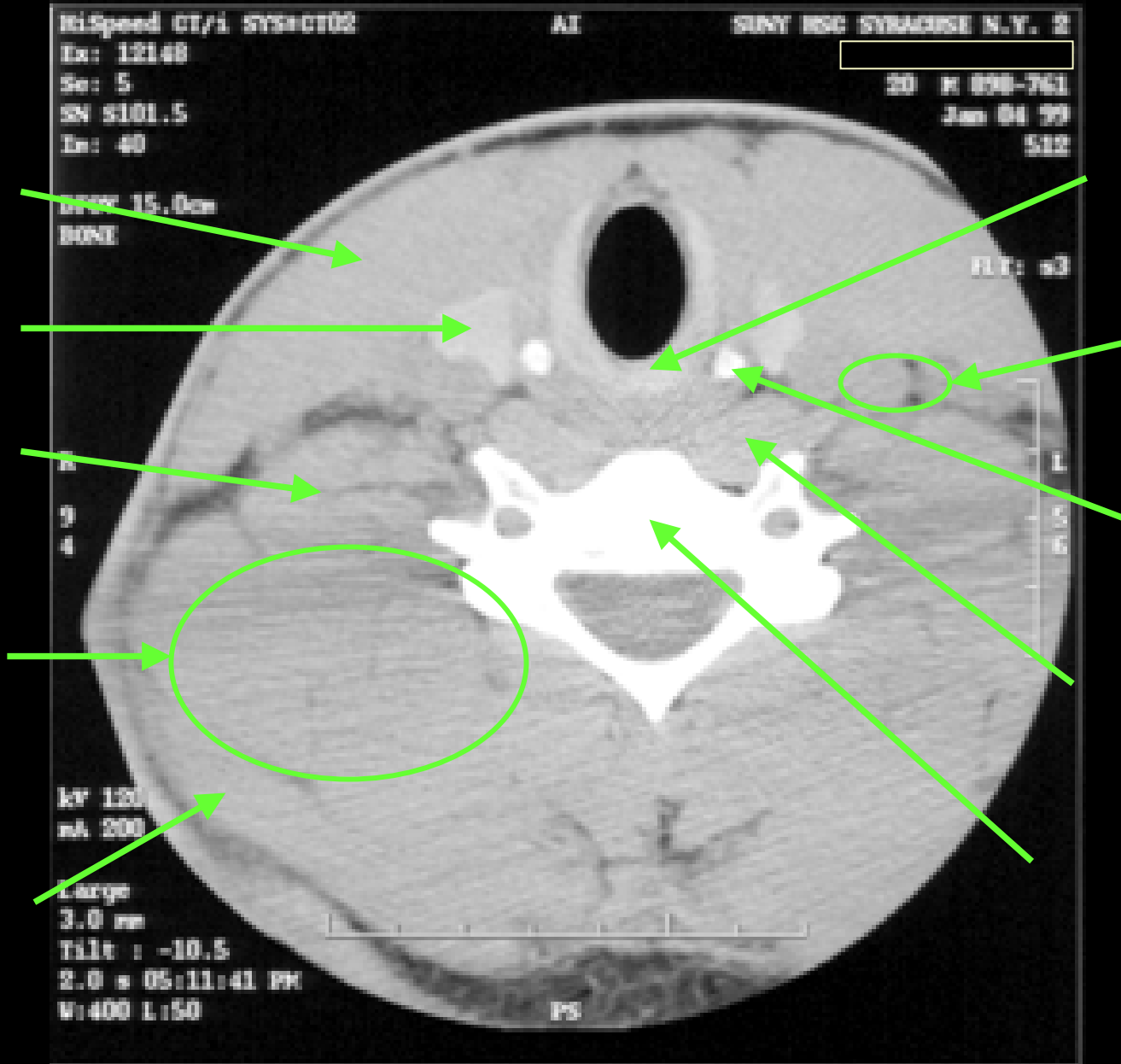


Go to next slide to see labels

Level 35

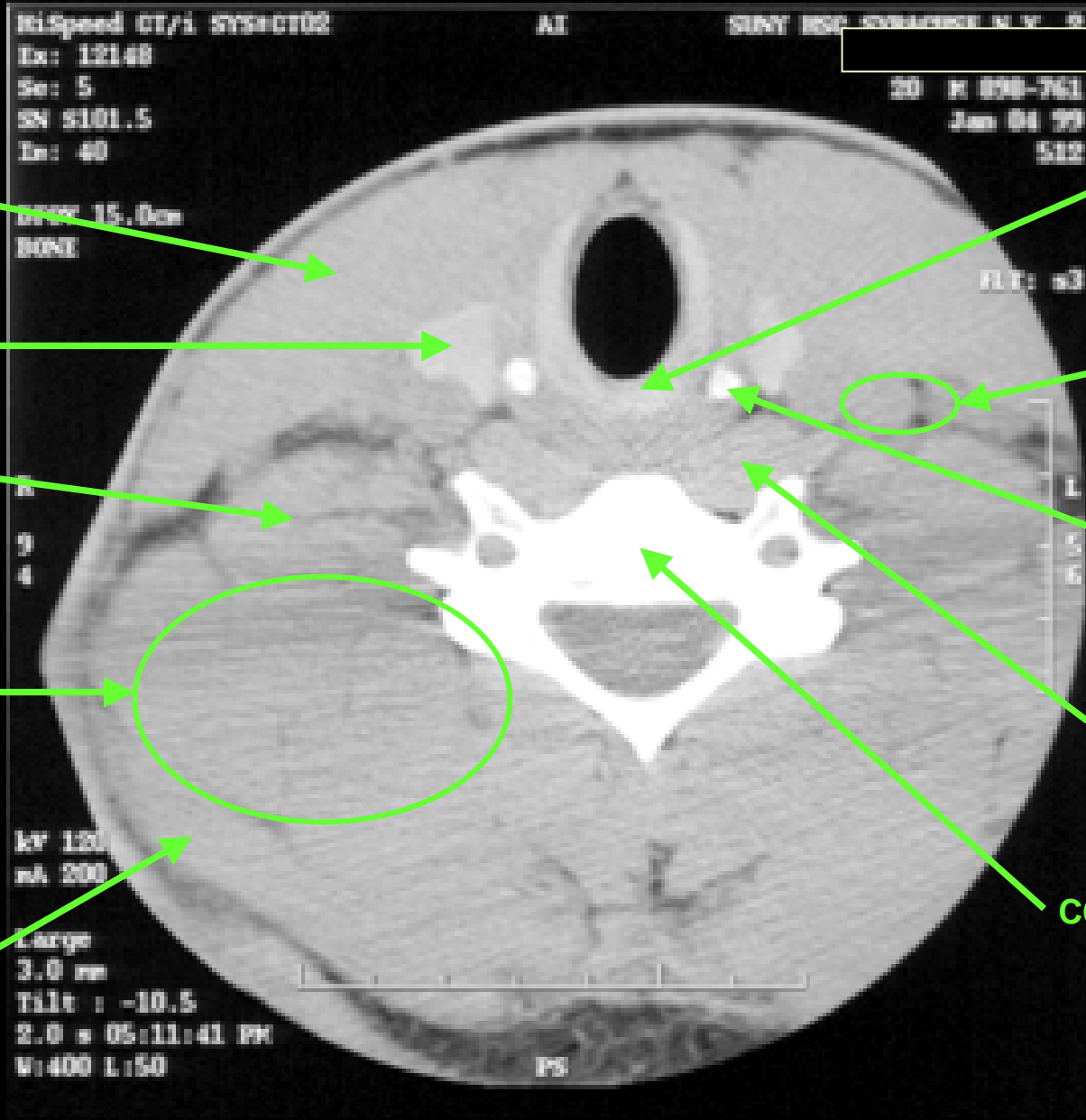


Level 40



Go to next slide to see labels

Level 40



SCM



Thyroid gland




Scalene muscle



Erector spinae muscle



Trapezius muscle




Cricoid Cartilage



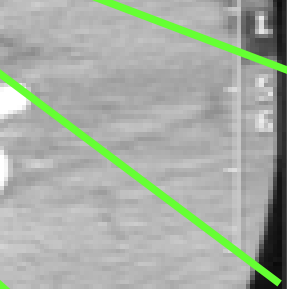
Carotid Sheath




Arytenoid cartilage



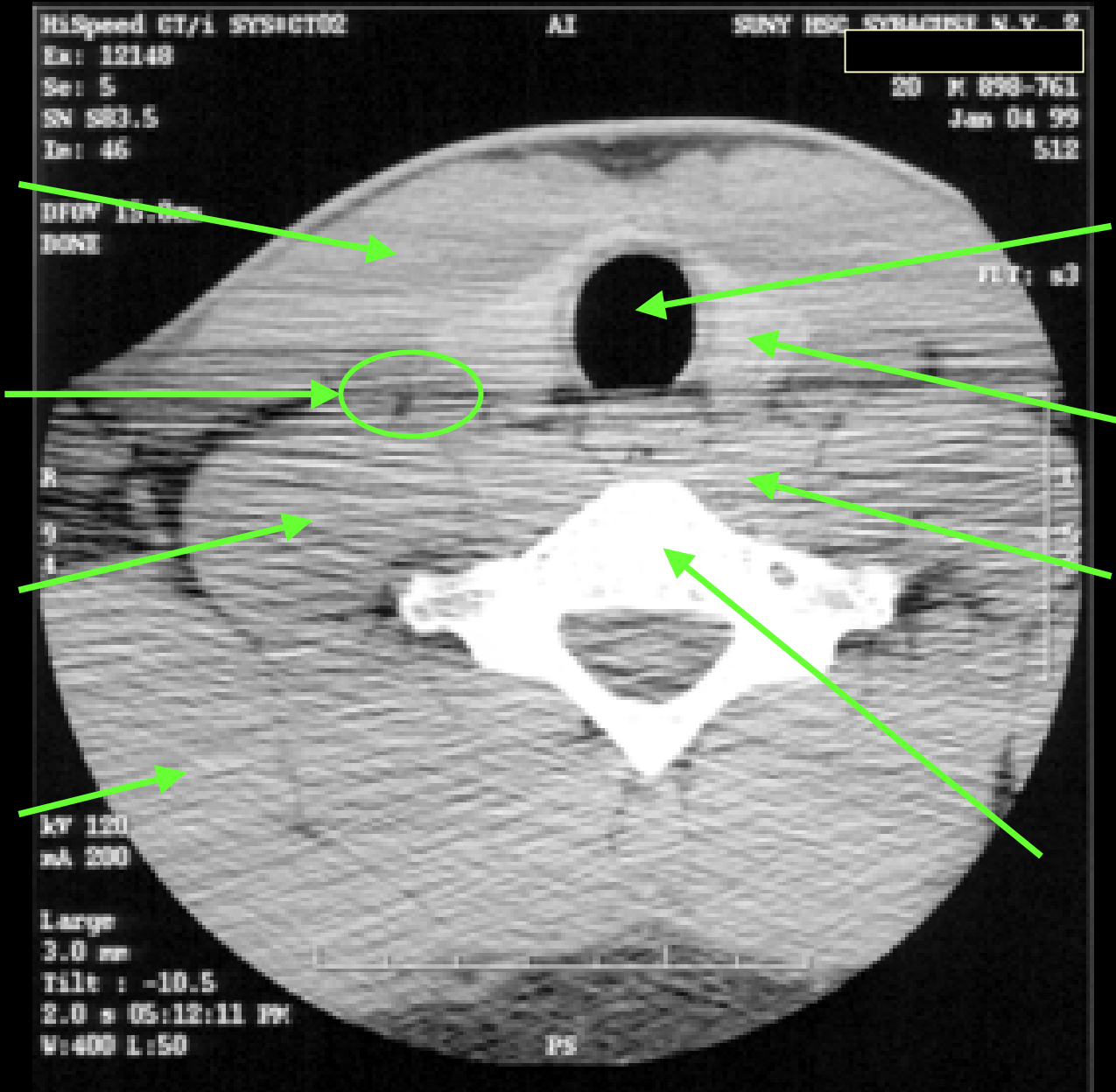
Pre-Vertebral muscle



C6

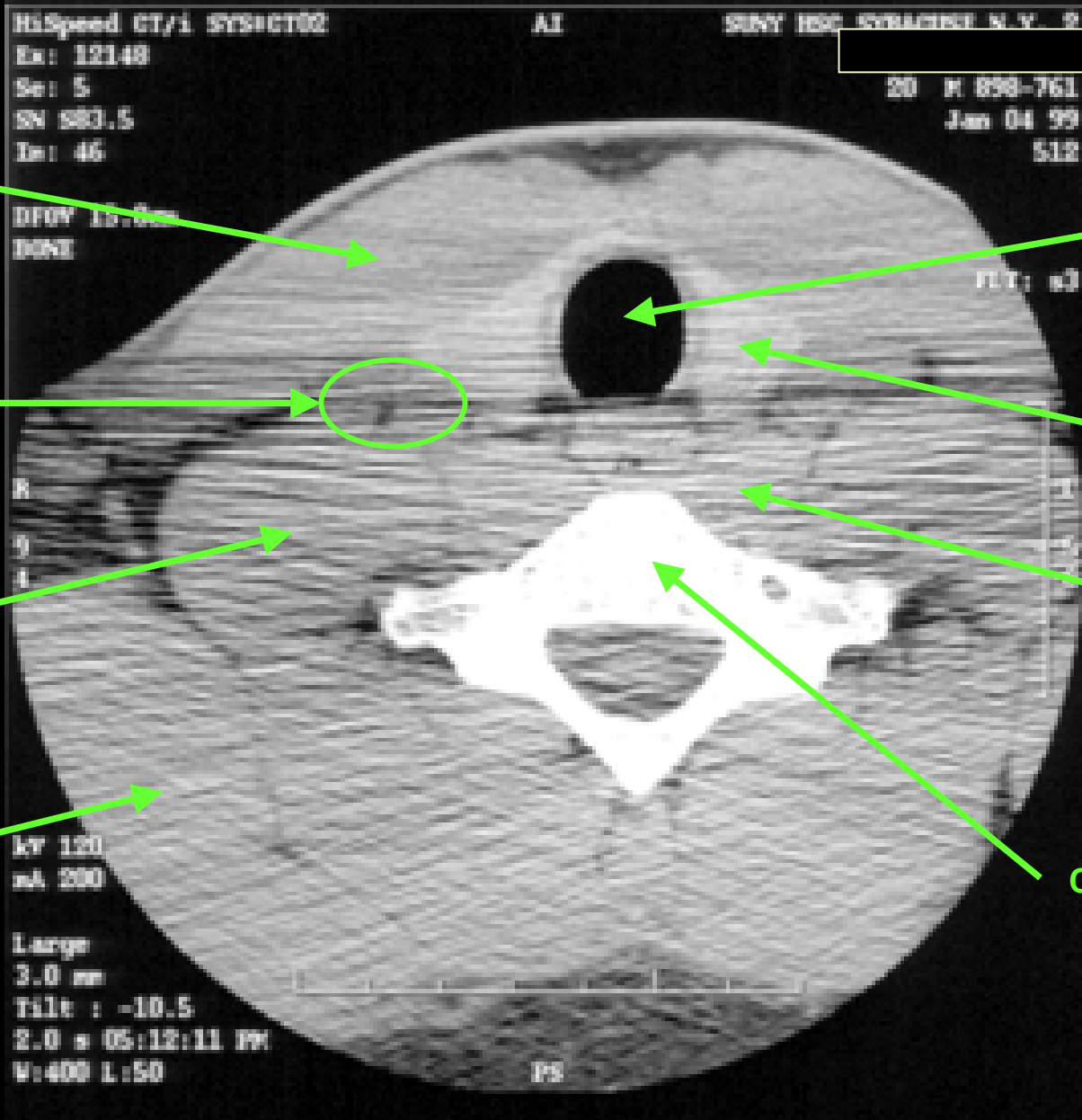


Level 46




Go to next slide to see labels

Level 46



SCM



Trachea




Carotid sheath



Thyroid gland




Scalene muscle



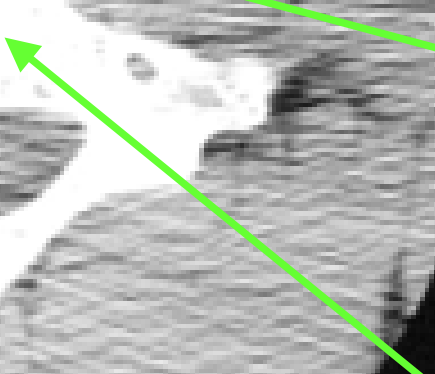
Pre-Vertebral muscle



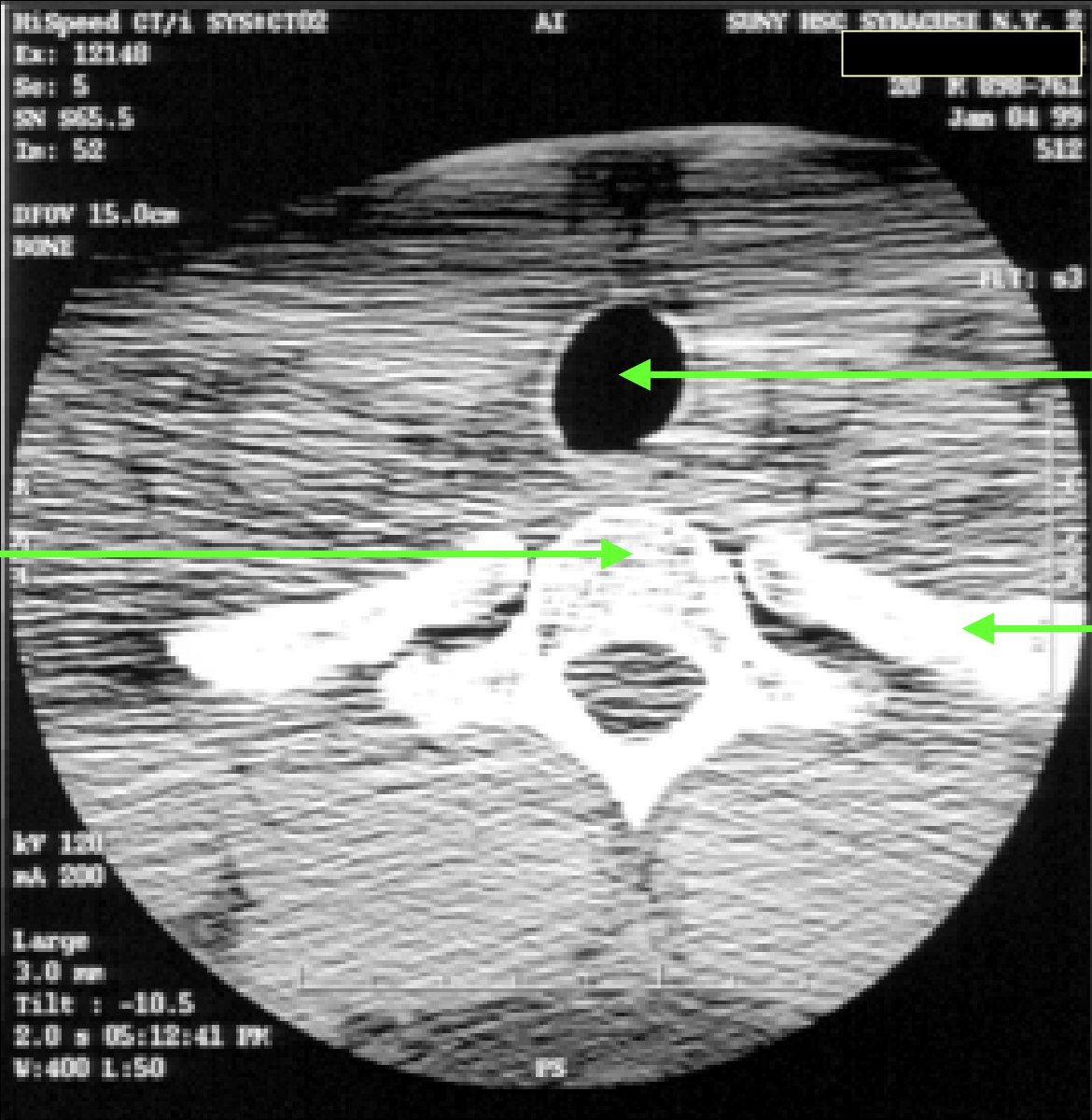
Trapezius muscle



C7



Level 52

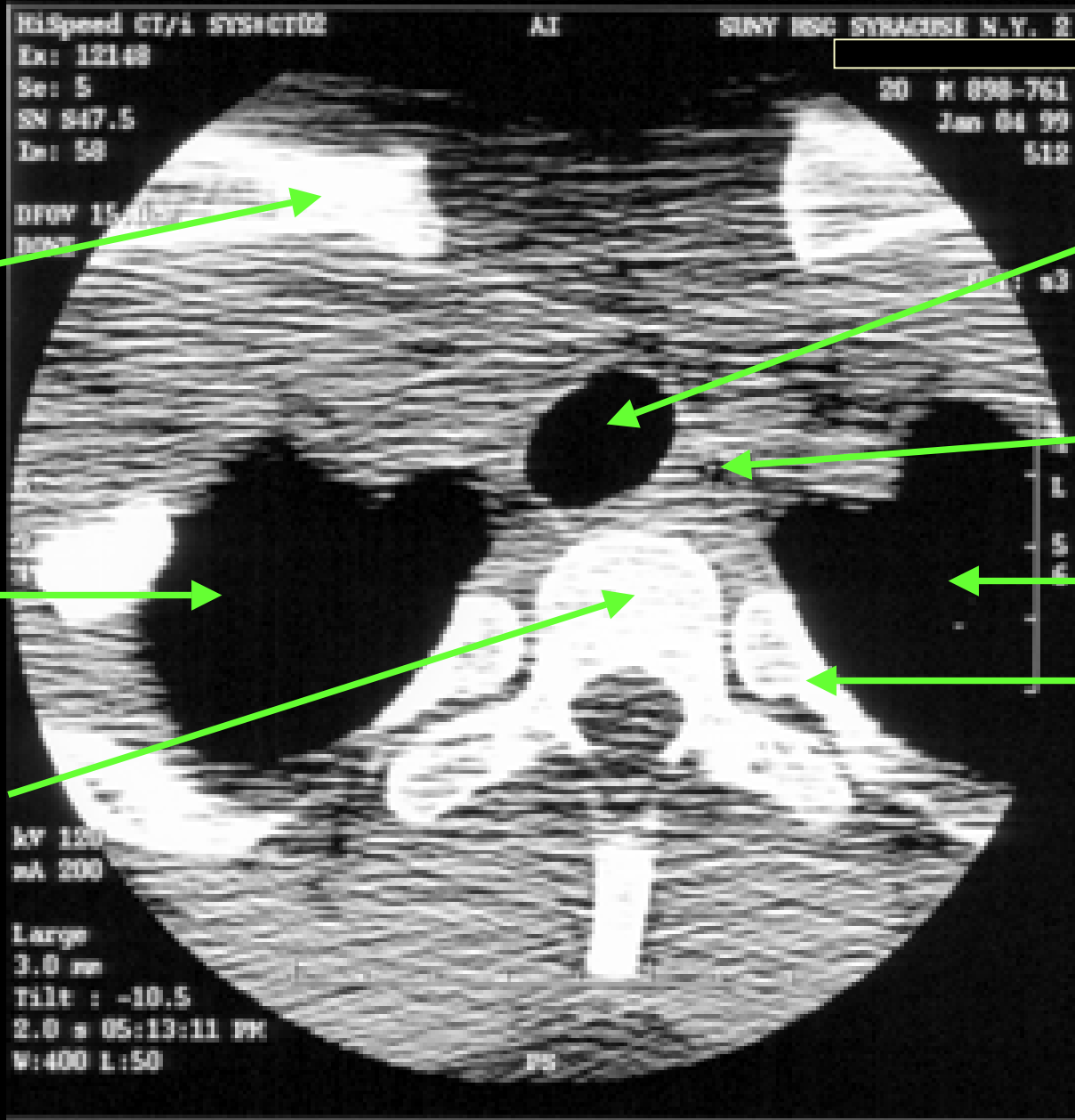


Trachea

T1

1st Rib

Level 58



Clavicle

Trachea

Esophagus

Apex of
Left Lung

Apex of
Left Lung

2nd Rib

T2